



ISSN: 0976-3376

Available Online at <http://www.journalajst.com>

ASIAN JOURNAL OF
SCIENCE AND TECHNOLOGY

Asian Journal of Science and Technology
Vol. 6, Issue 05, pp. 1393-1396, May, 2015

RESEARCH ARTICLE

MEASLY PORK – A HIDDEN HEALTH PROBLEM

*Dr. Y. Damodar Singh

Department of Veterinary Pathology, College of Veterinary Sciences & A.H., Central Agricultural University,
Selesih, Aizawl - 796014, Mizoram, India

ARTICLE INFO

Article History:

Received 21st February, 2015
Received in revised form
25th March, 2015
Accepted 30th April, 2015
Published online 31st May, 2015

Key words:

Cysticercosis,
Measly Pork,
Human Health.

ABSTRACT

Porcine cysticercosis is a disease caused by *Cysticercus cellulosae*, the larval stage of *Taenia solium*. Pig acts as intermediate host for perpetuate the life cycle of *C. cellulosae*. Human is the only natural host of adult stage of *T. solium* which causes taeniasis, a serious parasitic zoonosis. Cysticercosis in humans occurs due to the ingestion of diseased (measly) pork meat containing *C. cellulosae* or tape worm eggs when eating contaminated foods. The human has then become an accidental and "dead-end" intermediate host. Pigs, which are the "normal" intermediate host for this parasite, get infected with cysticerci when they ingest contaminated food and water with human faeces.

Copyright © 2015 Dr. Y. Damodar Singh. This is an open access article distributed under the Creative Commons Attribution License, which permits unrestricted use, distribution, and reproduction in any medium, provided the original work is properly cited.

INTRODUCTION

What is measly pork?

Pigs flesh containing cysticercus (larval form of pork tapeworm, *Taenia solium*) is called measly pork. The word measly can refer to measles, and, thence, to spotty and, thence, to something that is of little value.

How do you know if a pig is infected?

Pigs usually do not show signs of infection. A cysticercus infection (commonly referred to as measly pork or pork measles) is usually only found when the meat is inspected. Cysticerci are found chiefly in the muscles of the swine heart, tongue, forearm, thigh and neck, but can occur in other parts of the body. Intramuscular sites are the most common areas affected.

How does the tapeworm harm humans?

Man gets infection by eating uncooked measly pork. Cysticercus after entering small intestine becomes active. Proscotex of cysticercus evaginates and attaches to intestinal wall. Now proliferation of neck begins to form proglottids and

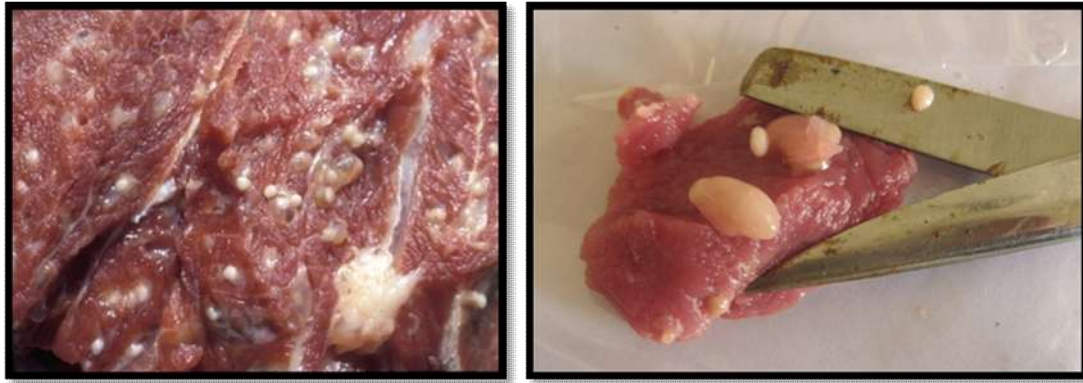the bladder is digested. In 10 to 12 weeks parasite becomes adult to start its life cycle again. The presence of an adult tapeworm in the intestine may cause non-specific symptoms such as abdominal pain, diarrhoea or constipation. Neurocysticercosis (NCC) is the most common parasitic infection of the brain affecting more than 50 million people all over the world. NCC is caused by infection of the larvae of *T. solium*. If someone ingests diseased (measly) pork meat containing larva forms of this tapeworm or ingests its eggs when eating contaminated foods, the parasite finds its way to the small intestine where they become mature. From here the parasite spreads to the brain to form of cystic lesions, also affecting the eyes, muscles or spinal cord.

What are the symptoms in humans?

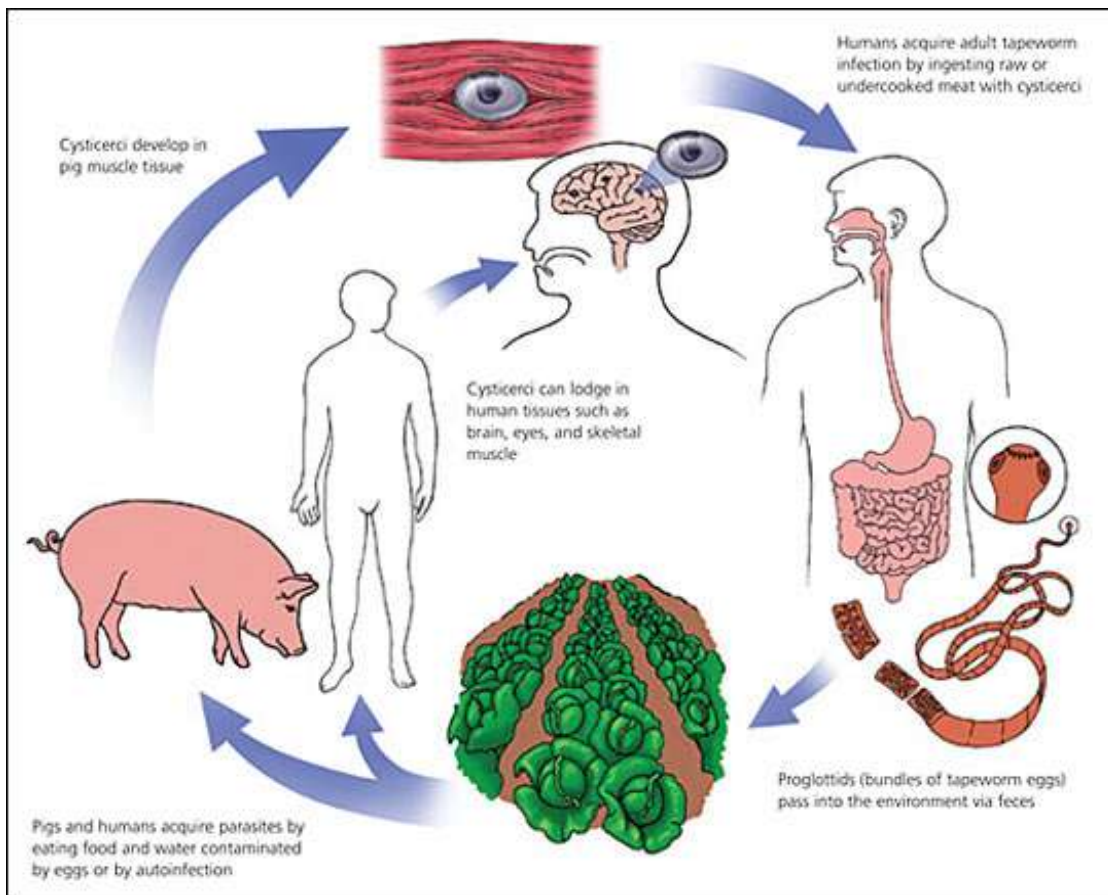
- Taeniasis (a gastrointestinal infection) symptoms include diarrhea, loss of weight, malnutrition, nausea and abdominal pain.
- Ophthalmic cysticercosis (when cysticercus encysted in the eye of the host) shows edema and hemorrhaging of the retina, blurred vision and inflammation of the choroid of the eye.
- In patients with Neurocysticercosis (NCC), the most common symptoms include headaches, nausea, vomiting, blurred vision, confusion, epileptic attacks, seizures, encephalitis and psychiatric manifestations.
- Intestinal impactions may occur in rare cases.

*Corresponding author: Dr. Y. Damodar Singh

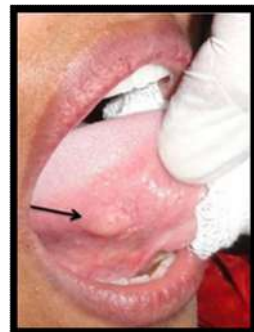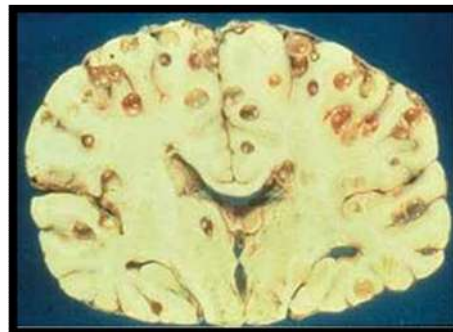
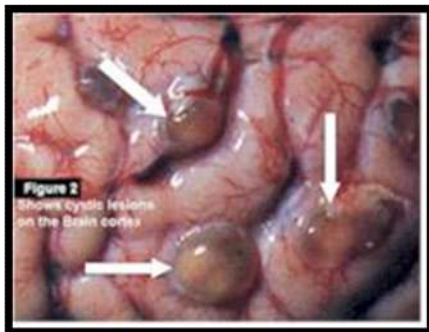
Department of Veterinary Pathology, College of Veterinary Sciences
& A.H., Central Agricultural University, Selesih, Aizawl - 796014,
Mizoram, India



Pork infected with pig tapeworm cysts



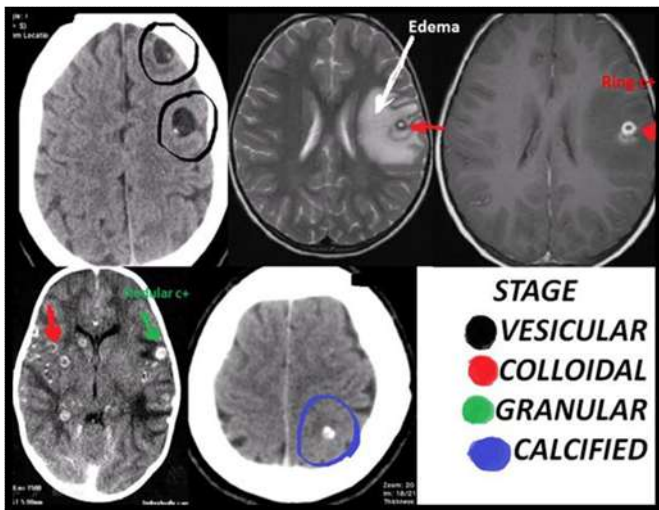
Life cycle of *Taenia solium* (Pork tapeworm)



Cystic lesions on the brain cortex, worm cysts in the human brain and tongue

How can NCC be diagnosed?

- Diagnosis of Neurocysticercosis in humans has greatly improved by introduction of MRI (Magnetic Resonance Imaging) & CT (Computed Tomography) scan.
- In general, MRI provides better image, detection and definition.
- However, the cost of MRI is high and the equipment is scarcely available in many endemic countries, and its sensitivity for the detection of calcified lesion is poor.
- CT remains the best screening neuroimaging procedure for patients with suspected neurocysticercosis.
- Immunodiagnostic techniques like Indirect Immunofluorescent Antibody Test (IFAT) and Enzyme-Linked Immunosorbent Assay (ELISA) can be used for detection of cysticercus-specific IgG antibody from the serum as well as from the CSF.
- Brain biopsy can be performed in cases where diagnosis remains questionable and lesion has not resolved.



Can people with NCC be treated?

- Anticonvulsants may be given for seizure control.
- Signs of increased intracranial pressure or apparent symptoms need for corticosteroid treatment.
- An effective anticestodal drug can be given for active or multiple cysts.
- Consult an ophthalmologist to examine for any signs of sub-retinal cysts.
- Consult a neurosurgeon if a biopsy or resection is called for or if the patient requires shunting because of hydrocephalus.
- Reserve neurosurgical intervention for cases of cysts that have failed to resolve with antihelminthic treatment and are causing severe neurologic sequelae. Resolution of lesions with medical management alone is superior and should be attempted first.
- Arrange neurologic follow-up care to manage seizures and any sequelae.
- Perform a follow-up MRI in 3-6 months or sooner if symptoms worsen or recur.

How can you prevent yourself from becoming infected?

- Cooking pork thoroughly.
- Washing hands frequently when preparing food.

- Using clean utensils to prevent cross-contamination during food processing.
- Properly disposing of human waste thereby preventing the contamination of food and drinking water sources.

How can you choose pork?

- The best kind of pork is fresh and pinkish in color and the fat is firm and white.
- The second quality has rather hard, red flesh, and yellowish fat.
- The poorest kind has dark, coarse grained meat, soft fat and discoloured kidneys.
- The flesh of stale pork is moist and clammy, and its smell betrays its condition.
- Measly pork has little kernels in the fat, and is unhealthy and dangerous food.

Prevention & Control

- Prevention of exposure to infected ova in the home and community is the most effective preventative measure.
- Examine stools from contacts using 3 consecutive daily specimens.
- Educate patients and their families regarding prevention.
- Emphasize improvement in general sanitation, health education, separation of pigs from humans, meat inspection and food preparation hygiene in endemic areas.

REFERENCES

- Aluja, A.S. de and Vargas, G. 1988. The histopathology of Porcine Cysticercosis. *Vet. Parasitol.*, 28 (½): 65-77.
- Aluja, A.S. de., Martinez, J. J. and Villalobos, A.N.M. 1998. *Tania solium* cysticercosis in young pigs: age at first infection and histological characteristics. *Vet. Parasitol.*, 76: 71-79.
- D'Souza, P.E. 1998. Studies on porcine cysticercosis with special reference to serodiagnosis. *J.Vet. Parasitol*, 12(1): 64.
- Deka, D. 1989. Epidemiology and immuno-diagnosis of certain common larval cestodes of domestic animals. *PhD Thesis submitted to G.B. Pant university of Agriculture and Tech., Pantnagar, India.*
- Deka, D.K. and Gaur, S.N.S. 1990. *Tania solium* cysticercosis in pigs in western parts of Uttar Pradesh. *J.Vet. Parasitol.*, 4(1): 59-63.
- Deka, D.K., Borkakoty, M.R. and Lahkar, B.C. 1985. Cysticercosis in domestic animals in North Eastern region of India. *Indian. J. Parasitol.*, 9(1): 83-85.
- Deka, D.K., Choudhury, S. and Chakraborty, A. 1995. Parasites of domestic animals and birds in Lakhimpur (Assam). *J.Vet. Parasitol.*, 9(1): 21-25.
- Dev Sarma, M.K. 1999. Some aspects of hydatidosis and other common larval cestodes of domestic animals. *M.V.Sc. Thesis submitted to A.A.U., Khanapara, Guwahati- 22, Assam.*
- Harrison, L.J.S., Joshua, G.W.P., Wright, S.H. and Parkhouse, R.M.E. 1989. Specific detection of circulating surface/secreted glycoproteins of viable cysticerci in *Taenia saginata* cysticercosis. *Parasite Immunol*, 11(4): 351-370.
- ICAR Progress Report, 2000-2001. Studies on Hydatidosis/Cysticercosis in different animals of N.E.

- Region. Dept. Parasitol., C.V.Sc, A.A.U., Khanapara, Guwahati-22, Assam.
- ICAR Progress Report, 2001-2002. Studies on Hydatidosis/Cysticercosis in different animals of N.E. Region. Dept. Parasitol., C.V.Sc, A.A.U., Khanapara, Guwahati-22, Assam.
- Kumar, D. and Gaur, S.N.S. 1994. *Taenia solium* cysticercosis in pigs. *Helm. Abstr.*, 63(10): 365-383.
- Markell, EK., John, DT. and Krotoski, WA. 1999. Medical Parasitology 8th Edn. Pennsylvania: Saunders.
- Molinari, J.L., Tato, P. and Sepulveda, J. 1992. Twinning in metacestodes of *Taenia solium*. *J. Parasitol.* 78(5): 920.
- Plain, B. 1991. Studies on the incidence of cysticercosis in pig and cattle with special reference to taeniasis in human being in Assam and Meghalaya. M.V.Sc. Thesis submitted to the Assam Agricultural University.
- Pramanik, A.K., Bhattacharyya, H.M. and Sengupta, D.N. 1985. Occurrence of *Cysticercus cellulosae* in slaughtered pigs in Calcutta and its public health significance. *Indian J. Anim. Hlth*, 24: 143-146.
- Sarma, G.C. 1977. Studies on incidence of human taeniasis and animal cysticercosis in Greater Guwahati area of Assam. M.V.PH. Thesis, University of Calcutta, West Bengal.
- Thornton, H. and Gracey, J.F. 1974. Textbook of Meat Hygiene. 6th Edition. Bailliere and Tindall, London.
- Vargas, M.G.D., Saldierna, U., NavarroFlerro, R., Acevedo Hernandez, A., Flisser, de. M.A. AND Aluja, A. S. de 1986. Localization of *Taenia solium* cysticercosis in different muscle region of swine and its significance in meat inspection. *Veterinaria Mexico*, 17(4): 275-279.
- World Health Organization, 1979. Parasitic Zoonosis, Report of a WHO expert committee with the participation of FAO Technical report series. 637.
