



ISSN: 0976-3376

Available Online at <http://www.journalajst.com>

ASIAN JOURNAL OF
SCIENCE AND TECHNOLOGY

Asian Journal of Science and Technology
Vol. 15, Issue, 11, pp. 13217-13220, November, 2024

RESEARCH ARTICLE

HOMEOPATHIC TREATMENT FOR THE MANAGEMENT OF GUTTATE PSORIASIS

*Dr. Vikas Jaswal

CHC, Chandigarh Branch, Dr Batra's Positive Health Clinic Pvt. Ltd., India

ARTICLE INFO

Article History:

Received 11th August, 2024
Received in revised form
18th September, 2024
Accepted 19th October, 2024
Published online 23rd November, 2024

Keywords:

Guttate psoriasis, Homeopathic,
Treatment.

ABSTRACT

Guttate psoriasis is a form of psoriasis whose appearance is small, drop-shaped, red lesions covered with silvery scales. This condition commonly affects the trunk, limbs, and scalp, and is more frequently seen in younger individuals, including children and young adults. This case study explores the homeopathic treatment of a 63-year-old male patient with guttate psoriasis, highlighting the gradual improvement in both the skin lesions and overall well-being over several months.

Citation: Dr Vikas Jaswal. 2024. "Homeopathic treatment for the management of Guttate Psoriasis", *Asian Journal of Science and Technology*, 15, (11), 13217-13220.

Copyright©2024, Dr Vikas Jaswal. This is an open access article distributed under the Creative Commons Attribution License, which permits unrestricted use, distribution, and reproduction in any medium, provided the original work is properly cited.

INTRODUCTION

Guttate psoriasis has round red lesions covered with silvery scales. It is often triggered by infections, particularly streptococcal throat infections, and can also be exacerbated by factors such as stress, skin trauma, or certain medications. Symptoms include itching, redness, and scaling, with rapid onset following a bacterial infection. Complications include emotional distress, secondary infections, and, in rare cases, psoriatic arthritis.

CASE PROFILE

A 64-year-old male presented with guttate psoriasis that had been ongoing for the past 6 months. The condition initially began with red, scaly lesions on the ear, which then spread to the scalp, legs, and elbows. The patient reported itching on the upper back, with burning sensations on the lower back. He had previously been prescribed allopathic and homeopathic treatments for the condition. The patient's medical history included diabetes mellitus (diagnosed 9 years ago), he also underwent surgery for an appendix removal and treatment for an obstructed kidney stone. Two years ago, he experienced a frozen shoulder, for which he underwent physiotherapy. His family history includes diabetes in his father and all relatives, except his mother.

Lifespace: A 64-year-old male with guttate psoriasis for the past 6 months presented with red, scaly lesions starting from his ear, spreading to his scalp, legs, and elbows, along with itching and burning sensations on his back. His medical history includes diabetes, for which he takes medication, along with treatment for hypertension,

cholesterol, appendix surgery, and kidney stone issues. He retired as a bank manager in 2020 and sold his house in Jammu, which he now regrets. Living with his wife while his children reside in Bangalore, he feels isolated and emotionally distressed. His emotional state has worsened, with increased anger and frustration, particularly when his wife is away. He has a history of alcohol consumption to cope with sleep issues and feels more isolated since the death of his pet in 2016. Despite these challenges, he remains sociable and maintains a strong desire for cleanliness and order around the house.

Physical General

App - Normal
Craving -
Aversion/Intolerance - Coffee - acidity in stomach
Ghee - In sabzi, Or Rice, Pickles - if takes in routine
Thirst - 2-3 ltrs/day
Urine - Normal
Stool - Normal
Thermals - ambi-thermal
Sweet - Profuse on back and scalp - non offensive, no staining
Sleep - Good 7-8 Hours
Dreams - of childhood house

Physical Generals

Diet	Non veg
Appetite	Normal
Desire	Non veg and spicy food
Aversion	Coffee , ghee , rice , pickles
Thermal Reaction	Ambi-thermal
Thirst	2 - liters/ increased
Stools	Normal
Urine	Normal
Perspiration	Profuse on back and scalp
Sleep	Disturbed
Dreams	Of childhood house which was in Kashmir

*Corresponding author: Dr Vikas Jaswal

CHC, Chandigarh Branch, Dr Batra's Positive Health Clinic Pvt. Ltd., India

Examination

Auspitz sign – positive
 Woods lamp—silvery white layer with inflammation

Past History


DM since 9 years
 Takes med 2 time /daily
 Gluconorm 1 mg
 Tenget M 1000
 Bp, Cholesterol - Atolrip 10 mg, Losacar, Neurobinion Forte
 Surgery for Appendix and Obstructed Kidney Stone
 2 years back, had frozen shoulder - physiotherapy
 F/H - Father – DM

Family History N.S.

Case analysis - Reportorial totality

Repertory used	Rubrics selected
Radar Opus/ Synthesis Repertory	– Ailments from contradiction – Alcoholism irritability with – Anger contradiction from – Delusions melancholy

Repertory screenshot



Selection of Remedy

Remedy	Reasons
Constitutional Remedy name Remedy potency Remedy dose	Most similimum constitution seen in this remedy Nux vomica 1M given as the case was chronic and mental generals were involved Stat dose given.
Acute Remedy name Remedy potency Remedy dose	Remedy reasons Petroleum given on the basis of the type of eruptions red, flaky and itchy, calc sulph 6x given as a biochemic booster for the atomic level action, mezerium given as the itching was severe so given sos.
Intercurrent Remedy name Remedy potency Remedy dose	Sulph 30 given as an intercurrent medicine to boost up the action of nux vomica

Miasmatic approach

Symptoms	Psora	Sycosis	Syphilis	Tubercular
Redness and itching		yes		
itching		yes		
bleeding			yes	
Abusive aggressive		yes		

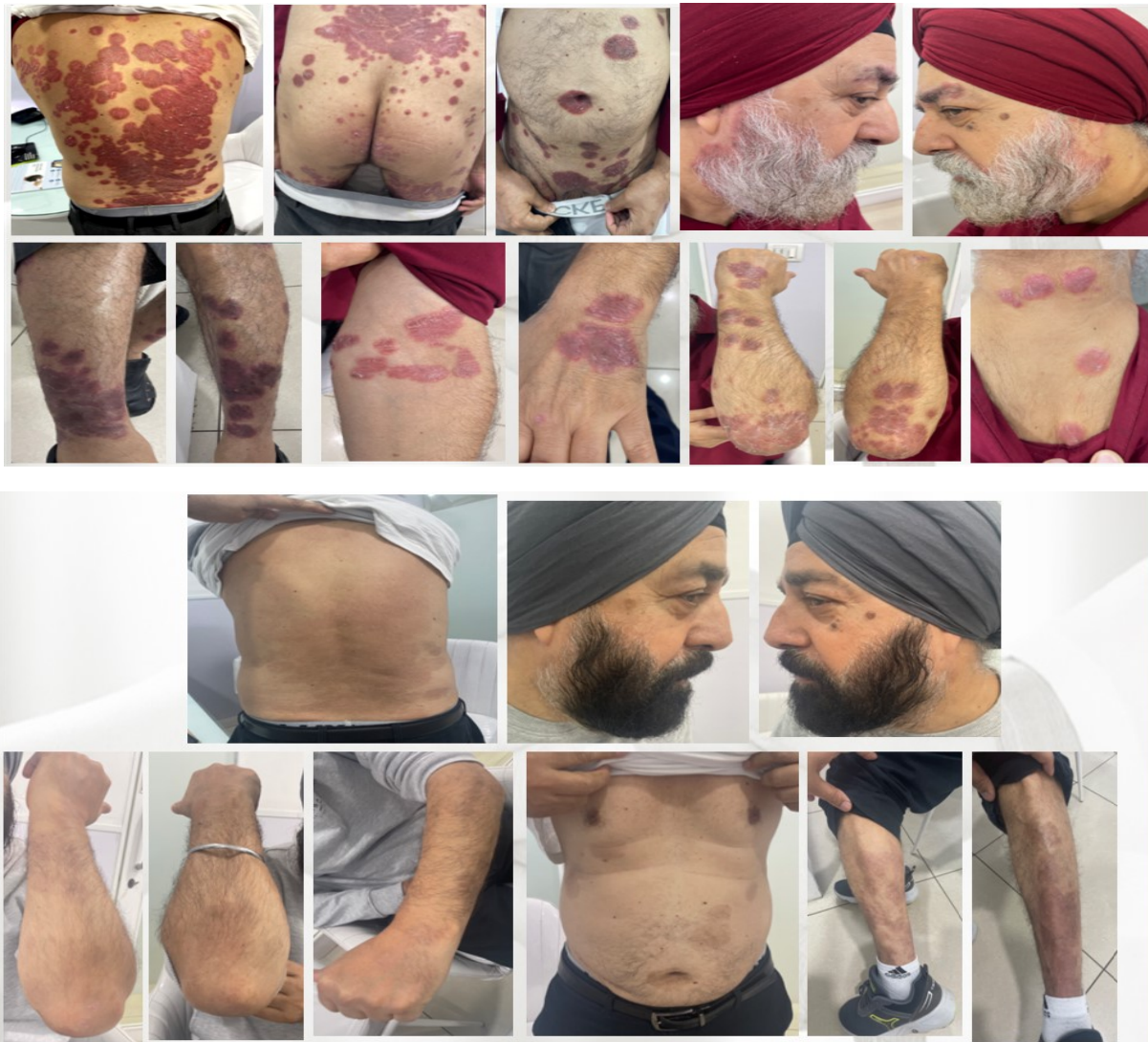MATERIALS AND METHODS

Radar Opus/Synthesis Repertory

RESULTS

Month	Progress	Prescription
1st month		- Lycopodium 1M
2nd month	Aggravated after leaving allo rx	Lycopodium 1M + Graphites 30 + Mezerium 30 + Kali Phos 6X
3rd month	Stable eruptions of 2nd visit but still no change	Nux Vomica 1M + Petroleum 30 + Mezerium 30 + Calc Sulph 30
4th month	Eruptions better and reduced from last time	Sac Lac 30
5th month	Few eruptions got vanished and rest stable	Sac Lac 30
6th month	Skin is getting much better gradually	Sac Lac 30
7th month	Eruptions over arms and legs are much better	Sac Lac 30
8th month	Eruptions stable like last time and case stand still	Sulphur 30 stat intercurrent
9th month	Skin is cured, all eruptions went off	Sac Lac 30
10th month	Cured	Sac Lac 30
11th month	Cured	Sac Lac 30
12th month	Cured	Sac Lac 30

The transformation



DISCUSSION & CONCLUSION

The patient presented with skin eruptions that initially worsened after discontinuing allopathic treatment. However, over the course of several months, homeopathic remedies, starting with Lycopodium 1M and later including Sac Lac 30, were used to manage and improve the condition. Other remedies like Nux Vomica, Petroleum, Mezerium, and Sulphur were also employed as intercurrent and supportive treatments.

The patient experienced gradual improvement, with eruptions significantly reduced by the 4th month. By the 9th month, the skin was fully healed, and the eruptions had completely disappeared. There were no further relapses, and the skin condition remained stable throughout the 12th month. The homeopathic treatment was effective in managing and curing the skin eruptions, with gradual improvement seen month by month. The case highlights the importance of personalized homeopathic care in addressing chronic skin conditions, demonstrating both symptom relief and complete recovery within a year.

ACKNOWLEDGMENTS

I take this opportunity to thank those who have helped and supported me personally and professionally during this case study.

REFERENCES

Boericke W. Pocket manual of homoeopathic Materia Medica & Repertory: comprising of the characteristic and guiding symptoms of all remedies (clinical and pathogenetic) including Indian Drugs New Delhi, India: B Jain publishers; 2002.

Clarke JH. A dictionary of practical materia medica. 2 vols.[in 3]. 1900.
Clarke JH. The Prescriber: A dictionary of the new therapeutics. Homeopathic Publishing Company; 1900.
Hahnemann S. Organon of medicine. B. Jain publishers; 2005.
Kent JT. Lectures on Homeopathic Philosophy. Sittingbourne, Homeopathic Book Service. 1990.
Kent JT. Lectures on homoeopathic materia medica. New Delhi, India: B Jain Publishing Company; 1980.
Lilienthal S. Homoeopathic therapeutics. B. Jain Publishers; 1998.
