



ISSN: 0976-3376

Available Online at <http://www.journalajst.com>

ASIAN JOURNAL OF  
SCIENCE AND TECHNOLOGY

Asian Journal of Science and Technology  
Vol. 13, Issue, 12, pp.12303-12305, December, 2022

## RESEARCH ARTICLE

### LARGE LINGUAL LIPOMA (YELLOW EPULIS): A CASE REPORT.

<sup>1</sup>Dr. Tarun Shetty and <sup>2</sup>Dr. Kamini Chavan

<sup>1</sup>Senior Resident, Department of General Surgery, Seth GS Medical College and KEM Hospital, Parel, Mumbai

<sup>2</sup>Assistant Professor, Department of ENT, Seth GS Medical College and KEM Hospital, Parel, Mumbai

#### ARTICLE INFO

##### Article History:

Received 09<sup>th</sup> September, 2022

Received in revised form

10<sup>th</sup> October, 2022

Accepted 15<sup>th</sup> November, 2022

Published online 28<sup>th</sup> December, 2022

##### Keywords:

Lingual lipoma, Ventral Tongue, Benign Tumor, Local Excision.

#### ABSTRACT

Lipoma is a common soft tissue tumor, occurring in different parts of the body. Lipoma originating in the oral mucosa is a rare presentation contributing around 1% to 5% of benign oral tumors. It typically presents as an asymptomatic yellowish oral mass. We herein discuss a case of a 50-year-old man who presented to our department with a tongue swelling that had existed for an unknown period. Clinical examination showed a yellowish, soft, nodular lesion measuring 8cm in diameter. Histological examination confirmed the mass as a benign lipoma. The lesion was excised completely surgically, and no recurrence was noted in the 1 year follow up period.

**Citation:** Dr. Tarun Shetty and Dr. Kamini Chavan, 2022. "Large lingual lipoma (yellow epulis): a case report.", *Asian Journal of Science and Technology*, 13, (12), 12303-12305.

Copyright © 2022, Tarun Shetty and Kamini Chavan. This is an open access article distributed under the Creative Commons Attribution License, which permits unrestricted use, distribution, and reproduction in any medium, provided the original work is properly cited.

#### INTRODUCTION

Lipomas are benign soft tissue neoplasms comprising of mature white adipocytes. The first description of oral lipomas was given by Roux in 1848 in a review of alveolar masses. He termed it as a "yellow epulis". They are the most common soft tissue mesenchymal neoplasms<sup>[1]</sup>. They mainly involve regions of the trunk, neck, shoulders, axilla. Around 15-20% cases involve the head and neck region. However, they are relatively uncommon in the oral and maxillofacial regions<sup>[2]</sup>. Specific anatomic locations within the oral and maxillofacial region include the parotid region, buccal mucosa, lips, submandibular region, tongue, palate, floor of mouth and vestibule. Infrequent locations of orofacial lipomas include the maxillary bones especially the mandible. Site predilection is most likely associated with the availability of adipose tissue which is high in the buccal mucosa due to the proximity of the buccal pad of fat and very low in the palate. Lipomas are usually described as long-standing soft nodular asymptomatic swellings covered by normal mucosa. Lipomatous benign tumor tissue is very similar to normal adipose tissue; however, lipoma metabolism differs, as it has been shown that the fat tissue of lipoma is not used for energy production during starvation periods as occurs with normal adipose tissue. And it is also surrounded by thin fibrous tissue.

Oral lipomas are diagnosed more frequently at a mean age of 50 to 62 years. Mean tumor size is 2.2 cm<sup>[2]</sup>. The overall incidence in the oral cavity is thought to be between 1% and 4% of all benign oral lesions<sup>[3]</sup>. Lipomas are more common in males than females, although several authors believe that there is not sex predominance<sup>[4]</sup>. Most of the oral lipomas are simple classic lipomas (80%), fibrolipoma, spindle cell lipoma, angiolipoma, salivary gland lipoma, pleomorphic lipoma or atypical lipoma<sup>[4]</sup>.

#### CASE PRESENTATION

A 50 yr old healthy male presented to us with a swelling on the dorsum of the tongue. The swelling was present for 2 years but there was no rapid increase in size. The patient had difficulty in talking but no complaints of dysphagia or dyspnea. Patient was tolerating orals very well but was complaining of difficulty in bolus formation recently. Swelling was not associated with bleeding or pain. There was no history of trauma. There was no history of swelling elsewhere in the body. Patient had no comorbidities. And had no positive family or personal history. On examination the swelling was globular in shape measuring 4cm x 6cm in size, soft in consistency, non-tender, present on the dorsal aspect of the tongue on the left side. (Fig 1) The superficial epithelium was intact no evidence of ulceration or bleed. No palpable neck masses.

\*Corresponding author: Dr. Tarun Shetty

Senior Resident, Department of General Surgery, Seth GS Medical College and KEM Hospital, Parel, Mumbai.

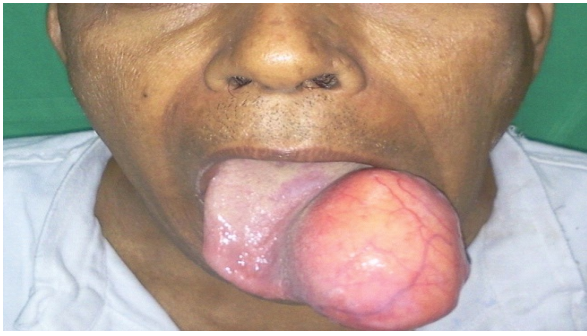

Figure 1. Large Lingual Lipoma

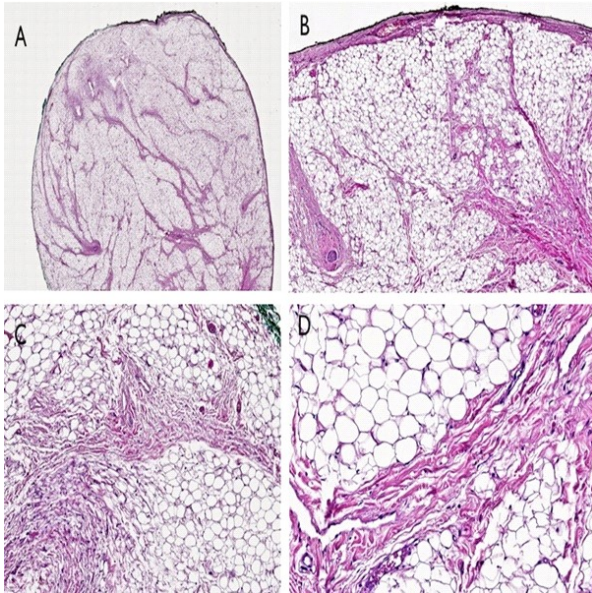


Figure 2. Histopathological examination of the oral lipoma. a) Histologic examination of the lesion stained with haematoxylin-eosin (x10): it is possible to observe the presence of mature adipose tissue and the presence of a large number of dense connective bundles subdividing the lesion into various lobules; b) an enlarged (x50) view of the lesion with the presence of lobulated fat and interspersed rope-like bundles of fibrous tissue; c) (x100) the two main histological components of the lesion were the presence of non-atypical and uniform adipocytes and the presence of oriented homogeneous collagen fibres; d) (x200) in this image, it is possible to observe the morphologic features of mature adipocytes: polygonal cells with a mono-vacuolated clear cytoplasm. No cellular atypia was found. Thus, a final diagnosis of fibrolipoma was made

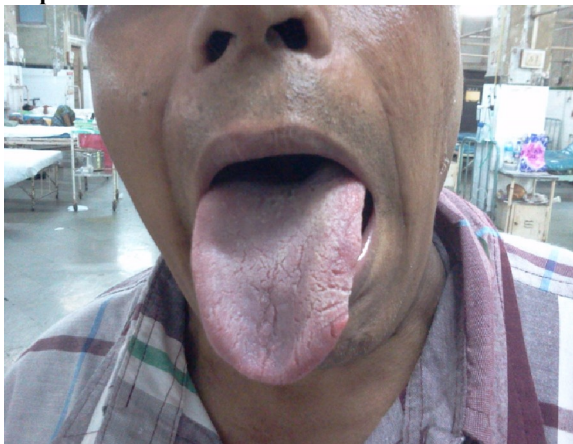


Figure 3. One year Post operative picture

## DISCUSSION

Lipomas are common tumors in the human body, but are less frequent in the oral cavity, comprising no more than 1- 5% of all the neoplasms. They commonly present as slow growing asymptomatic lesions with a characteristic yellowish colour and soft, doughy feel, in the buccal mucosa, floor of the mouth and tongue in the fourth and fifth decade generally without gender predilection. They may present as solitary or multiple lesions, for instance as in Gardner's or Bourneville's syndrome or as lipomatosis. Their clinical course is usually asymptomatic until they grow to large sizes. The majority remain un-ulcerated. In the above mentioned case the large size interfered with speech and mastication. Large tumors have been shown to cause dentofacial deformities, anterior open bite. The present case had an anterior open bite due to flaring out of the mandibular incisors and canines. The usual range in size is 0.2 to 1.5cm, with an average of 0.8cm<sup>[5]</sup>. The present case was 8 centimeters in diameter. The differential diagnosis includes ranula, dermoid cyst, thyroglossal duct cyst, ectopic thyroid tissue, pleomorphic adenoma and mucoepidermoid carcinoma angiolipoma, fibrolipoma and malignant lymphoma<sup>[6]</sup>. The definitive diagnosis is by microscopic examination which shows adult fat tissue cells embedded in a stroma of connective tissue and surrounded by a fibrous capsule<sup>[1]</sup>. (Fig 2). Lipoma has a characteristic radiographic appearance. On CT scan it shows a high density from 83 to 143 Hounsfield units with well or poorly defined margins depending on the capsule. Ultrasonography shows a lesion which is round or elliptical in shape with intact or mostly intact capsule. Most lipomas are hypoechoic with echogenic lines or spots<sup>[7]</sup>. Like other lipomatous tumors, the treatment of this tumour is exclusively surgical, and the clinical behaviour is best predicted by the completeness of surgical resection, as attested by surgical margins histologically free of tumour. The recurrence rate for infiltrating lipomas has been reported to be three to 62.5 per cent.

The length of time between initial excision and recurrence has been found to be between six months and 20 years<sup>[8]</sup>. Well encapsulated lipomas, as the present case, easily shell out with no possibility of recurrence or damage to the surrounding structures. It is still advisable to excise them with a little cuff of surrounding normal tissue to prevent recurrence but still conserving surrounding structures. Infiltrating lipomas are difficult to excise and when multiple there is a high risk for recurrence as adequate excision is difficult. Simple lipomas regardless their size are easy to excise without recurrence. This case was easily excised uneventfully. No recurrence noted even after one year. (Fig 3)

**Consent:** All essential consent was taken before reporting the case.

## CONCLUSION

A histological examination after removal of lipomas is imperative to exclude liposarcomatous degeneration, to detect the absence of a capsule, which requires a constant follow-up due to a high probability of recurrence. Furthermore, the small number of reviews regarding lipomatous tumors of the oral cavity suggests the necessity of more attention on the soft tissue tumors that could affect the oral cavity.

Thus, a possible expansion of the subtype classification and description of topographic issues may be revised in the future.

**Conflict of Interests:** None declared

**Competing Interests:** None declared

## REFERENCES

- Tettamanti L, Azzi L, Croveri F, Cimetti L, Farronato D, Bombeccari G, Tagliabue A, Spadari F. Oral lipoma: Many features of a rare oral benign neoplasm. *Head Neck Oncol* 2014 Jun 10;6(3):21.
- Fletcher C, Bridje JA, Hogendoorn P, Mertens F. WHO Classification of Tumours of Soft Tissue and Bone. 4th ed IARC press; 2013.
- Furlong MA, Fanburg-Smith JC, Childers EL. Lipoma of the oral and maxillofacial region: Site and subclassification of 125 cases. *Oral Surg Oral Med Oral Pathol Oral Radiol Endod.* 2004 Oct;98(4):441-50. doi: 10.1016/j.tripleo.2004.02.071. PMID: 15472660.
- Manor E, Sion-Vardy N, Joshua BZ, Bodner L. Oral lipoma: analysis of 58 new cases and review of the literature. *Ann Diagn Pathol.* 2011 Aug;15(4):257-61. doi: 10.1016/j.anndiagpath.2011.01.003. Epub 2011 Mar 29. PMID: 21447447.
- Epivatianos A, Markopoulos AK, Papanayotou P. Benign tumors of adipose tissue of the oral cavity: a clinicopathologic study of 13 cases. *J Oral Maxillofac Surg.* 2000 Oct;58(10):1113-7; discussion 1118. doi: 10.1053/joms.2000.9568. PMID: 11021705.
- Dattilo DJ, Ige JT, Nwana EJ. Intraoral lipoma of the tongue and submandibular space: report of a case. *J Oral Maxillofac Surg.* 1996 Jul;54(7):915-7. doi: 10.1016/s0278-2391(96)90549-2. PMID: 8676242.
- Burt AM, Huang BK. Imaging review of lipomatous musculoskeletal lesions. *SICOT J.* 2017;3:34. doi: 10.1051/sicotj/2017015. Epub 2017 May 5. PMID: 28474576; PMCID: PMC5418895
- Keskin G, Ustundag E, Ercin C. Multiple infiltrating lipomas of the tongue. *J Laryngol Otol.* 2002 May;116(5):395-7. doi: 10.1258/0022215021910906. PMID: 12081004.

\*\*\*\*\*