



ISSN: 0976-3376

Available Online at <http://www.journalajst.com>

ASIAN JOURNAL OF
SCIENCE AND TECHNOLOGY

Asian Journal of Science and Technology
Vol. 09, Issue, 02, pp.7587-7590, February, 2018

RESEARCH ARTICLE

ISOLATED MICROGASTRIA – A RARE ENTITY

*Rohan Sawant, Ankur Pramanick, Thahir Vu, Pratik Patil and Madan Manmohan

Department of Radiology, Dr. D. Y. Patil Hospital and Research centre, Nerul, Navi Mumbai, India

ARTICLE INFO

Article History:

Received 11th November, 2017
Received in revised form
15th December, 2017
Accepted 09th January, 2018
Published online 28th February, 2018

Key words:

Isolated, Microgastria,
Congenital.

Copyright © 2018, Rohan Sawant et al. This is an open access article distributed under the Creative Commons Attribution License, which permits unrestricted use, distribution, and reproduction in any medium, provided the original work is properly cited.

ABSTRACT

To report a case of isolated microgastria. To radiologically investigate a case of an 11-year-old boy who presented with a history of intermittent abdominal pain and decreased appetite since childhood. Conventional barium meal fluoroscopic study was performed to evaluate the gastrointestinal tract and appropriate radiographs were obtained. Contrast enhanced multislice multidetector Computed tomography scan was performed on a 128 slice machine. Axial, coronal and sagittal images were obtained. Radiological evaluation revealed; severely deformed stomach contour, moderately dilated esophagus and delayed emptying time. Congenital microgastria is a rare condition, which is usually associated with VACTERL anomalies. However, in this case there was no such association making it isolated condition and increasing its rarity.

INTRODUCTION

Congenital microgastria is a rare condition first reported in the 1800s. It usually occurs in conjunction with other congenital anomalies or more rarely alone. Till date, 59 cases have been reported of microgastria and only 5 cases of isolated microgastria (Jones and Cohen, 2007). There has been VACTERL association (Vertebral anomalies, Anorectal atresia, Cardiac anomalies, Tracheo- esophageal fistula and esophageal atresia, Renal and Limb anomalies), tracheoesophageal cleft, asplenia, malrotation of the intestines, situs inversus, megaesophagus, and upper limb anomalies such as radial, ulnar, and thenar hypoplasia (microgastria-limb reduction association). Increasing awareness and with the advent of diagnostic procedures there has been increased recognition of this condition. Reported therapy for microgastria has ranged from conservative dietary manipulation in patients minimally affected to surgical augmentation of the small stomach. We present a case of isolated microgastria in which radiological diagnosis was confirmed by barium meal fluoroscopic study and Contrast enhanced multislice multidetector Computed tomography scan.

MATERIALS AND METHOD

Conventional barium meal fluoroscopic study was performed to evaluate the gastrointestinal tract and appropriate radiographs were obtained. Contrast enhanced multislice multidetector Computed Contrast enhanced

enhanced multislice multidetector Computed tomography scan was performed on a 128 slice machine. Axial, coronal and sagittal images were obtained. Further this was confirmed on surgical exploration.

CASE REPORT

An eleven-year-old male child came to our institution with a history of intermittent abdominal pain and decreased appetite since childhood. The pain was aggravated since a past week. Detailed history revealed multiple attacks of excruciating pain since childhood, which was ignored most of the times. Clinical examination revealed severe pallor with weight and height below 3rd percentiles.

The patient was further advised for an endoscopic examination, however it was not of much help diagnostically. After which he was advised barium meal fluoroscopic study for evaluation of the gastrointestinal tract. It revealed severely deformed stomach contour, moderately dilated esophagus and delayed emptying time of the barium contrast. In correlation with the history and radiological evaluation we could narrow down our diagnosis to microgastria. Further to rule out any other VACTERL associations, detailed clinical examination, plain radiographs of the spine and abdominal ultrasonography screening was performed. However, it revealed no abnormality. CT scan revealed small caliber of stomach with adhesions involving the body of stomach, resembling hourglass appearance of stomach. Thus, in consideration of clinical and radiological findings the diagnosis of 'isolated microgastria' was made.

*Corresponding author: Rohan Sawant,

Department of Radiology, Dr. D. Y. Patil Hospital and Research centre, Nerul, Navi Mumbai, India.

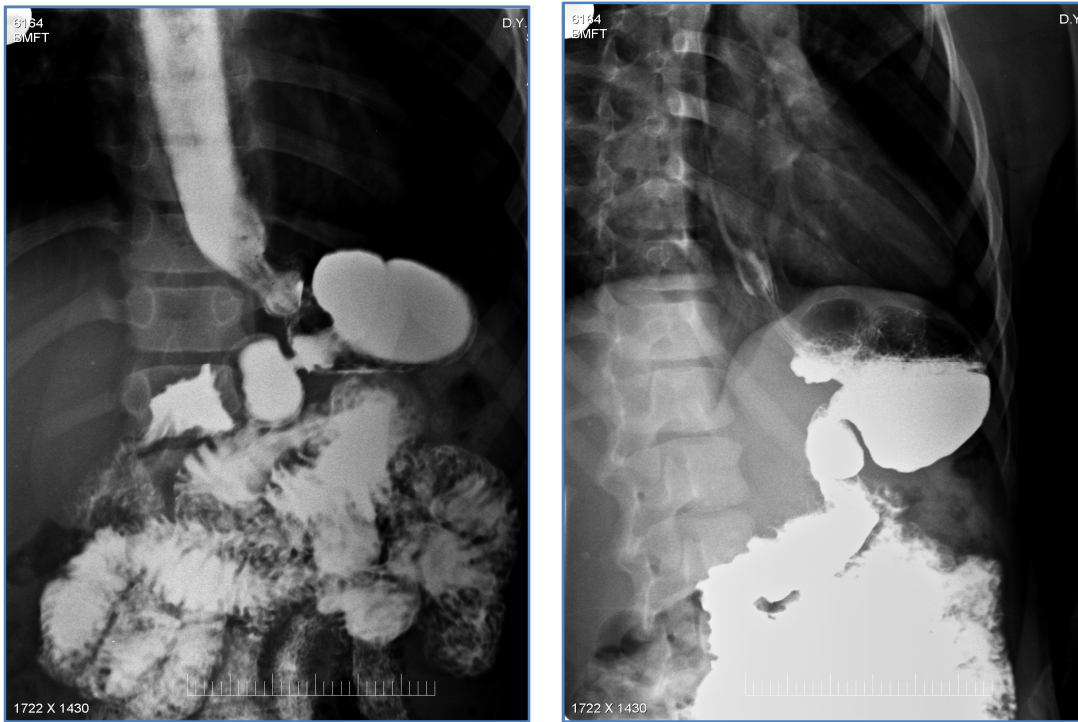


Figure 1 & 2. A severely deformed stomach contour moderately dilated esophagus and delayed emptying time of the barium contrast

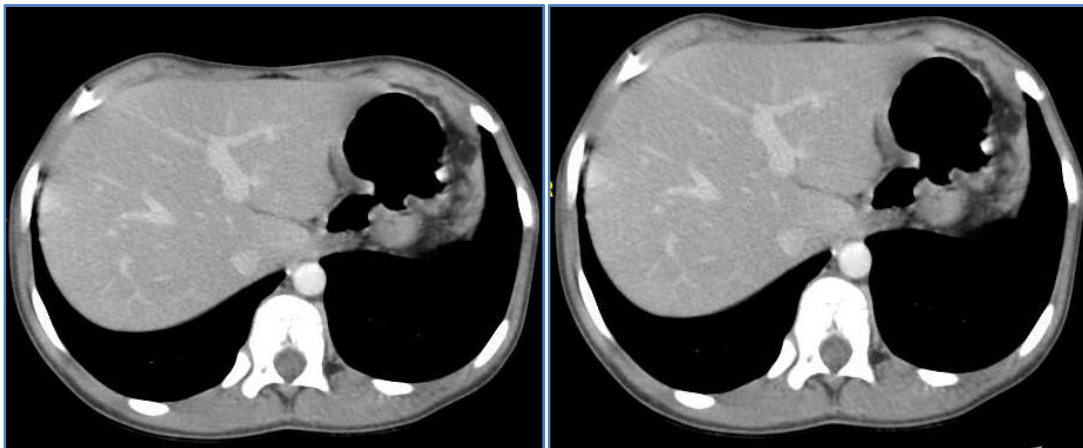


Figure 3 & 4. Axial CECT image reveal severely deformed stomach with reduced calibre and distensibility

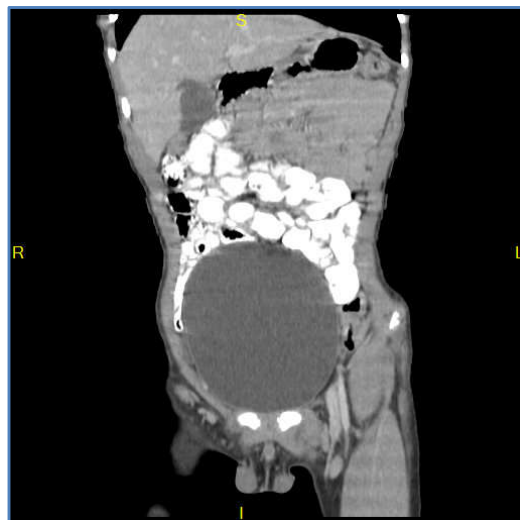

Figure 5. Coronal reformatted CECT image reveal severely deformed stomach with reduced calibre and distensibility

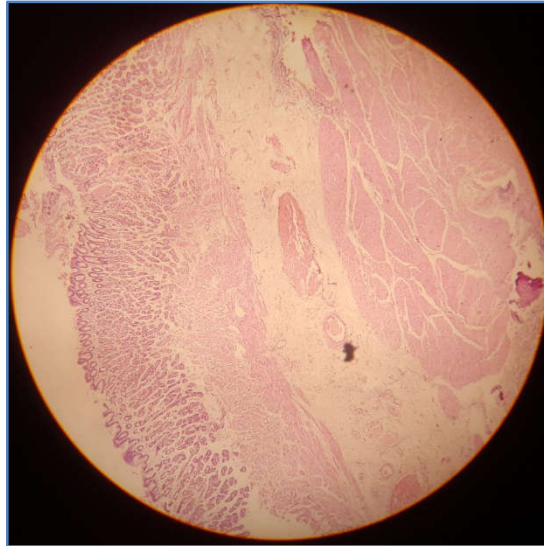


Figure 6. Section studied shows hypoplastic gastric mucosal lining epithelium showing ulceration at places. Underlying subepithelium appears normal with mild chronic inflammatory cell infiltrate. Features are consistent with radiological diagnosis of Microgastria

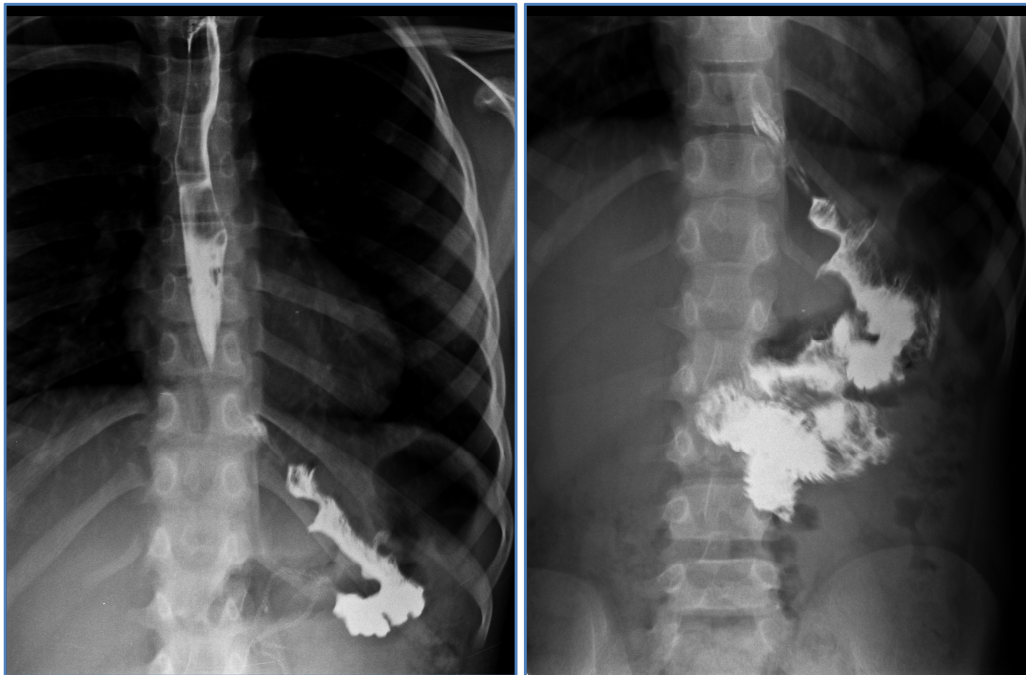

Figure 7 & 8. PostHunt-Lawrence pouch reservoir technique barium study reveal decrease in dilatation of the esophagus and normal filling jejunum

DISCUSSION

Microgastria (MG) is a rare congenital anomaly (Jones and Cohen, 2007). Normally, the stomach undergoes 90-degree clockwise rotation in the fifth week of embryological development. This occurs along with the migration of the pancreatic buds and the differentiation of dorsal mesogastrium into splenic anlage. Arrest in the early development of foregut results in MG (Langman, 1981). As the stomach and spleen both are developed from dorsal mesogastrium, associated splenic anomalies are not surprising (Kessler and Smulewicz, 1973). The association of limb cardiac, tracheoesophageal, vertebral and renal anomalies has been attributed to impairment of early mesodermal development (Leuder *et al.*, 1989). Prenatally MG mimics esophageal atresia.

Failure of visualization of fetal stomach early in second trimester suggests the possibility of congenital MG (Hill, 1994). Clinically MG presents as feeding intolerance with or without and failure to thrive (Ramos *et al.*). Caffey proposed that the esophagus dilates to take the storage function of the inadequate stomach (Hill, 1994; Gridamy, 1985). As MG is frequently associated with VACTERL anomalies it is necessary to investigate the child for the same. The treatment of MG is individualized. Short period of conservative treatment is warranted in less severe forms of MG with diet modification i.e. frequent and small size meals with increasing quantity to dilate stomach (Hochberger and Swoboda, 1974; Neifeld *et al.*, 1980). However if stomach fails to enlarge with this treatment surgical intervention is necessary. In patients with severe feed intolerance with gross failure to thrive, as in this case, gastric exclusion with oesophago-jejunal

anastomosis have produced satisfactory results (Lall *et al.*, 2006; Lall *et al.*, 2006). Hunt and Lawrence originally described creation of a food reservoir for carcinoma stomach by creating a food pouch (Hunt- Lawrence pouch) from a segment of jejunum (Hochberger and Swoboda, 1974; Neifeld *et al.*, 1980; Lall *et al.*, 1983) In 1980 Neifeld *et al* used double lumen jejunal pouch in congenital MG. In this procedure Roux en Y jejunal loop is formed to prevent alkaline reflux and a food pouch is made by anastomosing in as side-to-side fashion. It also allows drainage of duodenal contents. This treatment provides an adequate pouch for food storage and decreases incidence of dumping, lessens requirement for frequent feeding and facilitates eating a balanced diet. Microgastria is usually temporized with jejunal feedings. Operative intervention consists of jejunal feeding tubes and Hunt-Lawrence gastric augmentation. There are a few patients who have been reported with successful follow-up after a Hunt-Lawrence pouch (Menon *et al*).

Conclusion

The incidences of isolated congenital microgastria's are rare and are difficult to diagnose. Detailed barium meal study is the only way to diagnose this. Early diagnosis of this condition is difficult as the symptoms are very vague. So in a child presenting with feeding intolerance since birth, where any other cause is not found, the possibility of microgastria should be kept in mind.

REFERENCES

- Caffey, J. 1985. In: Paediatric X-ray diagnosis, 3rd edn. Year Publishers, Chicago, pp 486-487 Gridamy BR: Digestive system, in Silverman F (ed): Caffey's Pediatric X-ray diagnosis. Chicago, IL Year Book Medical, pp. 1440.
- Hill, LM. 1994. Congenital Microgastria: absence of fetal stomach and normal third trimester amniotic fluid volume: *J Ultrasound Med*, 13: 894-896.
- Hochberger, O. and Swoboda W. 1974. Congenital microgastria. A follow up observation over six years. *Paediatrics Radio*, 2: 207-208
- J Pediatric Surg. 2003 Oct;38(10):E4-6 Menon P¹, Rao KL, Cutinha HP, Thapa BR, Nagi B.
- J Pediatric Surgery.1996 Oct;31(10):1445-7 Ramos CT¹, Moss RL, Musemeche CA.
- Jones, V.S. and Cohen, CR. 2007. An eighteen year follow up after surgery for congenital microgastria-case report and review of literature. *J PediatrSurg*, 4:1957-1960
- Kessler, H., Smulewicz, JJ. 1973. Microgastria associated with agenesis of spleen. *Radiology*, 107: 393-396
- Lall, A., Morbito, A. *et al.*, 1983. Total oesophagogastric dissociation. *J PediatrSurg* 2006: 41: 342-346 Anderson KD, Guzzeta PC: Treatment of congenital microgastria and the dumping syndrome. *J PediatrSurg* 1983: 18: 747-750
- Lall, A., Morbito, A., Bianchi, A. 2006. Total gastric dissociations in difficult clinical situations. *Eur J PediatrSurg*, 16: 396-398
- Langman, J. 1981. Digestive system. In: Langman J(ed) Medical embryology. Williams and Wilkins, Baltimore pp 215-216
- Leuder, GT. and Fitz-James, 1989. A, Downton SB: Congenital microgastria and hypoplastic upper limb anomalies. *Am J Med Genet*, 32: 368- 370
- Neifeld, JP., Berman, WF., Lawrence, W. *et al*: Management of congenital 4icrogastria with jejuna reservoir pouch. *J PediatrSurg* 1980: 15: 882-885
