



ISSN: 0976-3376

Available Online at <http://www.journalajst.com>

ASIAN JOURNAL OF
SCIENCE AND TECHNOLOGY

Asian Journal of Science and Technology
Vol. 08, Issue, 12, pp.7250-7252, December, 2017

RESEARCH ARTICLE

ALOPECIA AREATA IN DOWN SYNDROME: TREATMENT WITH SYSTEMIC STEROID - AN OBSERVATION

***Mohammad A. Hye**

Professor, Department of Dermatology, Jalalabad Ragib-Rabeya Medical College,
Patantula Sylhet, Bangladesh

ARTICLE INFO

Article History:

Received 18th September, 2017
Received in revised form
26th October, 2017
Accepted 17th November, 2017
Published online 30th December, 2017

Key words:

Alopecia Areata,
Corticosteroid,
Down Syndrome.

Copyright©2017, Mohammad A. Hye. This is an open access article distributed under the Creative Commons Attribution License, which permits unrestricted use, distribution, and reproduction in any medium, provided the original work is properly cited.

ABSTRACT

Down syndrome (DS) is the most common congenital abnormality affecting numerous organs including skin and is associated with an increased incidence of alopecia areata (AA). DS is an extensively researched condition but AA seldom received appropriate attention. AA in DS is very refractory to treatment and there are only few relevant published data are available in medical literature. Two cases of alopecia areata associated with Down syndrome are presented here. These patients were treated with a short course of prednisolone; a good result was observed in one case but that was unsatisfactory in another case. The disease relapses in both cases within few months of treatment.

INTRODUCTION

Down Syndrome (DS) is a congenital condition characterized by mental retardation and distinct physical features. The cutaneous manifestations of DS are numerous and Alopecia Areata (AA) is recognized as a common dermatological condition. Owing to advances in medical care and changes in attitude, the life expectancy of the DS patients is improving. A good number of research papers is published in medical literature regarding physical and psychological aspects of this disease. But papers related to AA and other cutaneous aspects of DS are not enough in number. Still, there is no standard treatment for AA associated with DS and only few papers are available regarding treatment of this condition. But AA is a disease which significantly affect quality of life of patient. An appreciation and higher research of this disease is very important for comprehensive medical care as well as quality of life of these patients.

CASE-1

A 13 years old Bangladeshi girl presented with nonscarring hair loss in scalp for last 3 years. The clinical expression was an oval patch, 4cm 3 cm in diameter in parietal region of scalp. The patch was uninfamed, with no scaling and with empty hair follicles (Fig-1). Few "exclamation mark" hairs were seen around the edge of patch.

*Corresponding author: Mohammad A. Hye,
Professor, Department of Dermatology, Jalalabad Ragib-Rabeya
Medical College, Patantula Sylhet, Bangladesh.

Her physical appearance was compatible with that of DS and following features were observed (Fig-2): epicanthic fold, brachicephaly, and depressed nasal bridge, upward angle of eyes, short broad neck and wide gap between first and second toes. Routine laboratory data were between normal ranges. An interview with her family revealed that she had learning disability otherwise she was psychologically sound; she love socializing, singing, however, she was anxious for her loss of hair from last few months. She had only one brother and nobody of his family members had any relevant clinical conditions. She was a diagnosed case of DS and received several therapies in different institution by both internist and dermatologist. She applied topical steroid and topical minoxidil for a longtime and did not get any notable result. I prescribed her systemic prednisolone 20 mg daily for 10 consecutive days and another 4 days for tapering the doses. She attended after 1month with around 70% hair regrowth. Patient did not complaint any significant side effects of the drugs. She was maintained with topical potent steroid for next 3 months, however a relapse was observed within one month after discontinuation of treatment (Fig3).

CASE-2

A 8 years old Bangladeshi boy presented with loss of hairs in occipital and parietal regions of scalp for last 2 years. The area of alopecia was extensive and was spread in all the occipital region, extending upto parietal region (Fig-5). There was a isolated patch in parietal region also with a diameter of 2

cm. In frontal region there was also extensive area of alopecia which made him a wide forehead person (Fig-6).

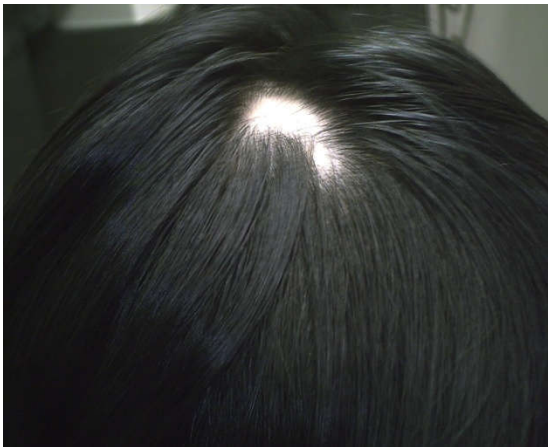

Fig1: Oval shaped patch of AA in parietal region of scalp

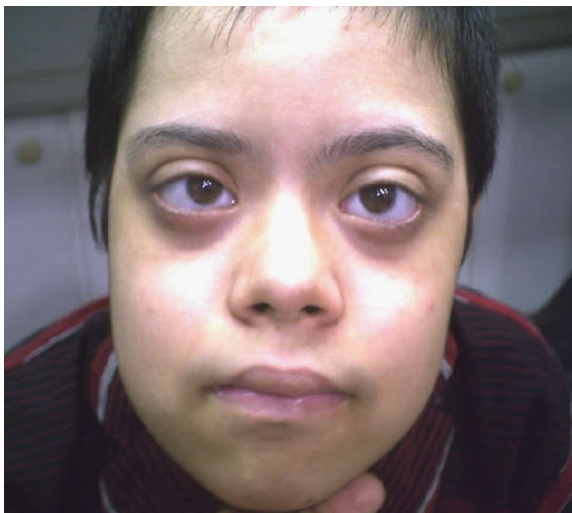


Fig 2: Phenotypic manifestations of DS

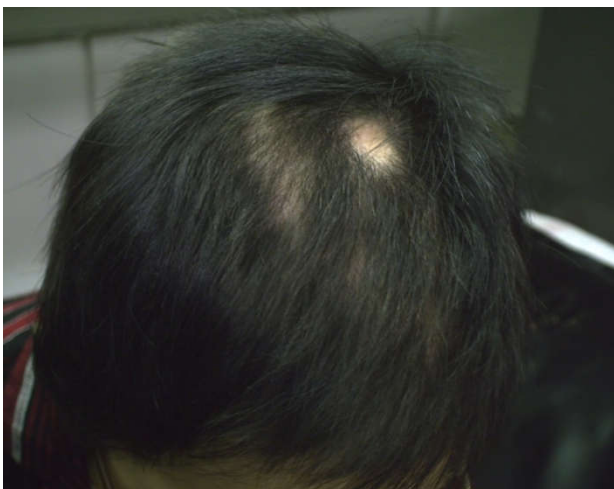

Fig. 3. Patch of AA ,one month after discontinuation of treatment

On examination, no hair follicles in the lesional area were found and also there were no scaling or erythema. He had no other dermatological manifestation except a lesion of Tinea in right forearm. Following phenotypic features were

noted in physical examination (Fig-4): epicanthic fold, brachiocephaly, short broad neck and protruding macroglossia. A psychiatric report revealed poor intelligence and learning disability. Routine laboratory data were within normal range.

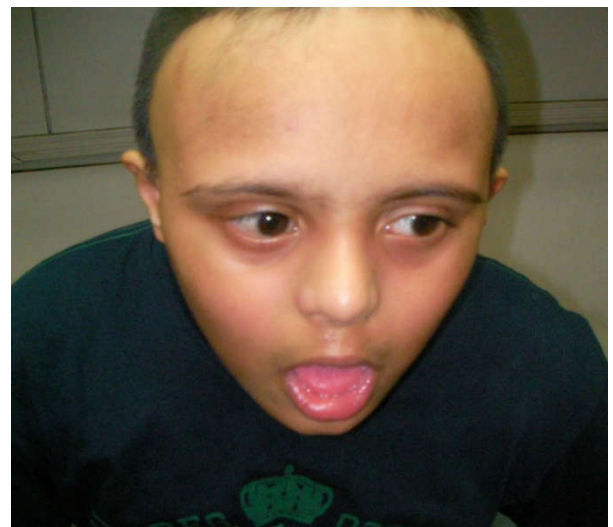

Fig. 4. phenotypic appearance of Down syndrome

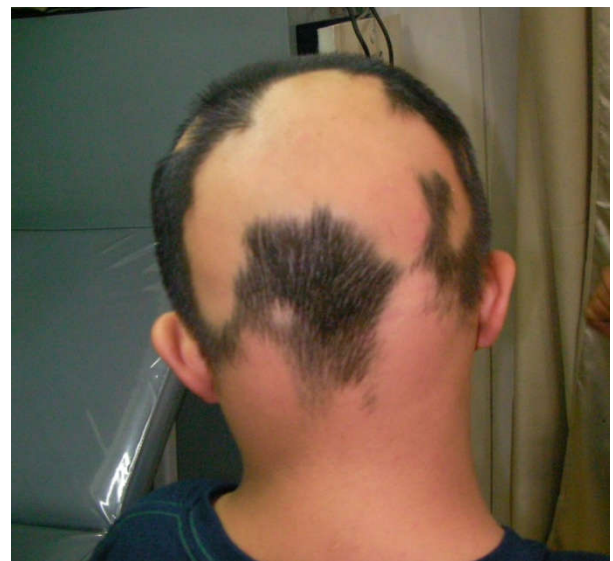

Fig. 5. Extensive area of alopecia in posterior occipital and part of parietal region of scalp

Patient was treated with systemic Prednisolone 20 mg daily for 10 days and another 4 days in tapering dose. The response was observed after one month; hair started to grow in 30% of lesional area. The parents of the patient informed us that the drug was well tolerated except mild gastritis and weight gain. We prescribed topical clobetasone propionate as a maintenance therapy. Patient returned back after one month with relapse of the disease.

DISCUSSION

Alopecia areata (AA) is recognized as a common skin disease among people with Down syndrome (DS). The prevalence reported in two large samples (Dermatology, 2002; Rengasamy Sureshbabu, 2011) ranges from 3 % (Dermatology, 2002) to 9.4 % (Rengasamy Sureshbabu, 2011). Schepis et al found the prevalence of 3% and their cases were within 5 to 10 yrs range (Dermatology 2002).

In one study in India, prevalence was 9.4% (Rengasamy Sureshbabu, 2011) Du Vivier and Munro reported 60 cases of AA in a series of 1000 people with DS (6%) (Anthony Du Vivier, 1975).

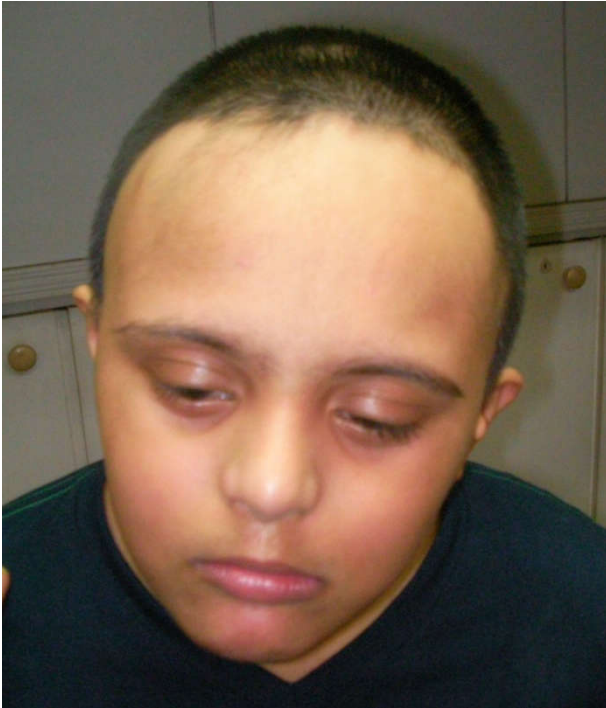

Fig. 6. Alopecia in frontal area of scalp

IN another survey in Iran the prevalence was 11% and their mean age was 11.2 years (Daneshpazhooh, 2007). The etiology of AA in DS is still unknown. Du Vivier and others investigated about immunological cause, however, no conclusive evidence is found in favour of this etiology^[3]. Recently the distal 10mb region of the long arm of the chromosome 21, which is also called Down Syndrome Critical Region 2 (DSCR2) has been proposed to be associated with many of the abnormalities seen in DS (Vasa et al., 2005). Several treatment modalities were tried and none revealed good results. However, there is a lacking of good numbers of standard trial regarding treatment of this condition. It is important to standardize the treatment modalities of AA associated with DS. For childhood AA, topical and/or intralesional corticosteroid is the first line treatment for limited involvement and squaric acid dibutyl ester is the treatment of choice of treatment for patients with extensive involvement⁽⁶⁾. In a clinical study in Singapore, it was found that the conventional treatment modalities response poorly in case of AA with Down syndrome (Tan et al., 2002). Occasional improvements have been reported with topical dinitrochlorobenzene (DNCB) (Hatamochi, 1984).

In our case study, both of the patients were under 12 years of age. Case-1 was a girl with only a single patch of AA and case-2 was a boy with extensive involvement. Both of the cases had a treatment history of conventional topical therapy but both experienced very poor/no result. It indicate that AA associated with DS is unresponsive to conventional topical treatment. I started treatment with systemic prednisolone, And it revealed excellent result in case 1 and a moderate response in case-2. I can hypothesize from this findings that response to systemic steroid in patient with single/isolated patch of AA is better than that of extensive involvement.

Conclusion

AA is a frequent disease in people with DS, often has an onset in childhood, and usually unresponsive or partially responsive to conventional therapy and there is always a relapse after the end of treatment. I have tried with systemic steroid and observed a good response in one case and moderate in another but relapse of the disease was observe d within few months in both cases. In the medical literature there is no standard trial with systemic steroid in case of AA associated with DS. Author like to emphasize more research in this arena so that we can be able to render comprehensive medical care to the patients of Down syndrome who deserve best medical care and better life in this 21st century.

REFERENCES

- Anthony, Du Vivier, Dowling D. Munro. 1975. Alopecia Areata, Autoimmunity, and Down's Syndrome. *British Medical Journal*, 1,191-192.
- Daneshpazhooh, M., Nazemi, T.M., Bigdeloo, L. et al. 2007. Mucocutaneous findings in 100 children with Down's syndrome. *Pediatr Dermatol*. May-June; 24(3):317-20. *Dermatology* 2002; 205:234-8.
- Hatamochi, A., Ueki, H. 1984. Successful treatment of alopecia areata with dinitrochlorobenzene in a patient with Down's syndrome. *J Dermatol*. Apr; 11(2):191-3.
- Rengasamy Sureshbabu, Rashmi Kumari, Subramaniam Ranugha et al. 2011. Phenotypic and dermatological manifestations in Down syndrome. *Dermatology Online Journal*. Feb 17(2):3.
- Tan, E., Tay, Y.K., Giam, Y.C. 2002. A clinical study of childhood alopecia areata in Singapore. *Pediatr Dermatol*. Jul-Aug; 19(4):298-301.
- Vasa, J., Brown, Y. Greenfield, D. et al. 2005. Molecular and cellular characterization of the Down syndrome critical region protein 2. *Biochem Biophys Res Commun*. 328(1):235-42
