



ISSN: 0976-3376

Available Online at <http://www.journalajst.com>

ASIAN JOURNAL OF  
SCIENCE AND TECHNOLOGY

Asian Journal of Science and Technology  
Vol. 08, Issue, 12, pp.7115-7120, December, 2017

## CASE REPORT

### KARTAGENER SYNDROME, GRANULOMATOUS CHEILITIS AND EXTRA ORAL MANIFESTATION OF ACTINOMYCOSIS IN A CHILD PATIENT: CASE REPORT

<sup>1</sup>Yasmin Nawal De Freitas Ashoury, <sup>2</sup>Ruth Andia-Merlin, <sup>3</sup>Carlos Eduardo Allegretti,  
<sup>4,\*</sup>Camila Correia dos Santos, <sup>5</sup>Rodolfo Georgevich Neto and <sup>6</sup>Elcio Magdalena Giovani

<sup>1</sup>Dental Surgeon - Faculty of Dentistry, Paulista University

<sup>2</sup>Master and Adjunct Professor of the Disciplines of Integrated Clinics and Patients with Special Needs - Faculty of Dentistry, Paulista University

<sup>3</sup>Master Doctor - Full Professor of Integrated Clinical Discipline - Director of the Institute of Health Sciences of the Faculty of Dentistry of the Paulista University

<sup>4</sup>PhD Student, Master - Adjunct Professor Radiology - Faculty of Dentistry, Paulista University

Master's student - Faculty of Dentistry, Paulista University

<sup>5</sup>Master Doctor - Full Professor of the Disciplines of Integrated Clinics and Patients with Special Needs, and

<sup>6</sup>Permanent Professor of the Postgraduate and Research Course - Master and Doctorate in Dentistry - Faculty of Dentistry of the Paulista University

#### ARTICLE INFO

##### Article History:

Received 20<sup>th</sup> September, 2017  
Received in revised form  
05<sup>th</sup> October, 2017  
Accepted 29<sup>th</sup> November, 2017  
Published online 30<sup>th</sup> December, 2017

##### Key words:

Oral Manifestation,  
Kartagener's Syndrome,  
Leishmaniasis,  
Fistula.

#### ABSTRACT

Kartagener's syndrome and granulomatous cheilitis are rare entities and are rarely discussed in the literature, and when still associated with the facial manifestation of actinomycosis, triggers severe aggravations in the patient's systemic and oral conditions. The objective of this study is to highlight the importance of multiprofessional work for an early diagnosis, as well as to emphasize the need for knowledge of the patient's systemic and oral health for a safe and quality care. It is also necessary to carry out more detailed studies on the correlation of Kartagener's Syndrome, granulomatous cheilitis and other manifestations, both oral and general, in order to establish effective and recommended therapeutic conducts in the conduction of the treatments, offering the patient integral health promotion and improvements in quality of life. This present case report consists of clinical and laboratorial assistance for diagnoses and treatment behaviors of the infantile patient. The clinical examination evaluated the systemic health, severity of the infection, volumetric increase of the upper lip and constant drainage of the extra-oral fistula with odor (sulfur granules). The patient had numerous foci of infection as residual roots of deciduous teeth, besides the tooth from which the fistula originated, and oral hygiene totally compromised. Laboratory tests were performed for differential diagnosis of leishmaniasis (Montenegro's reaction) for lip lesions - taking into account the origin of the patient from the northern region of the country, an endemic region in Brazil (Piauí), and incisional biopsy of the lip to confirm the diagnosis of granulomatous cheilitis. A prophylactic antibiotic was prescribed for the tooth extraction and drainage of extrabuccal fistula. We found total remission of extrabuccal fistula and significant regression of lip edema after removal of infectious foci. What was noticeable was the emotional improvement of the patient who at the time of diagnosis was generally and psychologically weakened. This is a clinical case that reports the simultaneous presence of three serious and rare factors in a pediatric patient, stressing the essential role of the Dentist, working together with the multidisciplinary team to diagnose, treat and improve the quality of life of the compromised patient

Copyright©2017, Yasmin Nawal De Freitas Ashoury et al. This is an open access article distributed under the Creative Commons Attribution License, which permits unrestricted use, distribution, and reproduction in any medium, provided the original work is properly cited.

#### INTRODUCTION

The kartagener syndrome was first described by Siewert in 1904, and established by the Polish Manes kartagener in 1933, being characterized by the presence of the triad composed by chronic pansinusitis, bronchiectasis and situs inversus with

**\*Corresponding author: Camila Correia dos Santos,**  
PhD Student, Master - Adjunct Professor Radiology - Faculty of Dentistry, Paulista University  
Master's student - Faculty of Dentistry, Paulista University.

dextrocardia (Carlen 2005; Gupta et al., 2012; Chang et al. 2017), which is an expressive disorder that shows the situs inversus and can be found in approximately 50% of the patients, being a congenital condition where the organs of the thorax and abdomen are transposed, together with the presence of chronic sinusitis and bronchiectasis. The genetic incidence is estimated at 1 / 25,000. Currently, the syndrome has been renamed to primary ciliary dyskinesia, since there was a defect in the structural organization of the cilia of the epithelium of

the lining of the respiratory tree, being a complete syndrome with severity of mobile cilia disease, caused by ciliary defects in different parts of the organism. This pathology is hereditary, but not well established. the defect in the structure of the cilia causes uncoordinated and inexpressible beats, modifying all the mucus secretion removal of the inhaled particles, culminating in rhinitis, sinusitis, otitis, bronchitis and pneumonia, these pictures being recurrent, but bronchiectasis is the predominant pulmonary complication Ferkol *et al.*, 2012; Raid *et al.*, 2014; Behan *et al.*, 2017). Patients diagnosed with primary ciliary dyskinesia may present with chronic productive cough, diffuse panbronchiolitis, sterility, chronic otitis media, and lesions located mainly in respiratory broccoli and recurrent respiratory infections. and when the diagnosis is late and of exclusion, there may be progressive impairment of pulmonary function and digital clubbing (congenital alteration characterized by increased diameter of distal phalanges and nail changes) in older patients. the diagnosis can be determined through electron microscopy by analysis of the ultrastructure and the functioning of the cilia (Bush *et al* 2007, Kurkowiak *et al* 2015, Behan *et al* 2017)/. Granulomatous cheilitis (GC) is a noninfectious granulomatous disease characterized by recurrent asymptomatic labial edema, resulting in permanent fibrosis and / or permanent lip swelling, and may be associated with facial paralysis and lingua plicata, forming the complete triad of the syndrome of Melkersson-Rosenthal (SMR), and there are scientific epidemiological reports that show no predilection for sex.

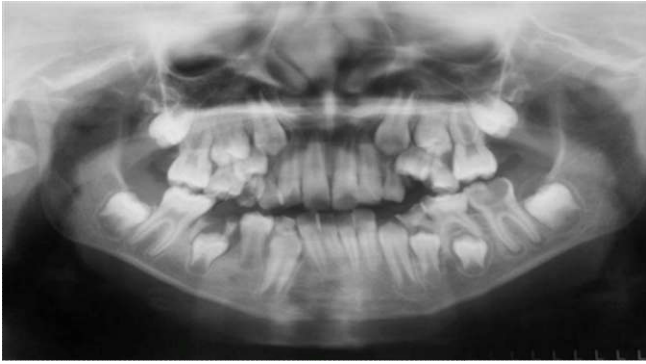It is a rare disease because its prevalence is 1 / 30,000 individuals, and its first manifestations occur more frequently in the second decade of life, and to this day its etiology and pathogenic mechanisms remain unknown (Alana *et al.*, 2010; to 2017). Actinomycosis is a rare bacterial infection caused by the microorganism of the genus actinomyces, composed of a heterogenous group of anaerobic bacteria, gram positive, non-acid-resistant, filamentous appearance. theactinomyces are commensal saprophytes components of the normal human buccalmicrobiota, and in the presence of imbalance between the host and the microorganism becomes a pathogen. the species actinomycesraelli is the most common, but there are many others, such as: *a. naeslundii*; *a. odontolyticus*; *a. viscosus*; *a. meyeri*; *propionibacteriumpropionicum*. cervicofacial location is the most common, and may affect the perimandibular, laterocervical, major salivary glands, floor, mouth, masseter, parapharyngeal space and upper jaw, but other locations are also amenable as abdominopelvic and pulmonary. dental caries, cysts of inflammatory origin, ingestion of foreign bodies, bacterial plaque, tartar and even idiopathic causes are important predisposing factors to be considered. Clinically, actinomycosis is characterized as an acute, rapidly progressive infection or as a chronic, slowly spreading lesion with fibrosis formation, usually by the presence of a hardened mass surrounded by a fibrous wall with central abscess area and purulent secretion, with a tendency to focus on the tissues, diffusing through the soft tissues, sometimes draining through fistulas. the secretion may or may not have large yellowish particles representing colonies of bacteria, termed sulfur granules. The diagnosis consists in the characterization of the sulfur granules and the material of a suspected lesion, the histopathological analysis is carried out by culture of the biopsied tissue. (Puri *et al.*, 2016; Bent *et al.*, 2017). We present an account of a rare clinical case of a child patient with katargener's syndrome, and with granulomatous

cheilitis associated with the manifestation of actinomycosis simultaneously, where the means of diagnosis, the clinical aspects, recommended therapeutic measures are reported, as well as to explain the need for a comprehensive evaluation of patients presenting with any isolated symptom, to enable an early diagnosis. The objective of this study was to elucidate new data to the related professionals and those who research the subject, so that they are attentive, accompanying the patients and waiting for the eventual appearance of this malformation, and that they can as early as possible establish the diagnosis, execution of the conduct to be taken in the conduct of each case.

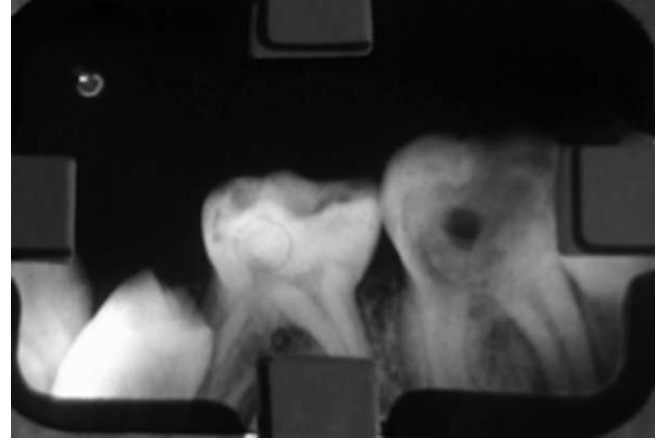### Case Report

Patient FRF, female, 11 years old, leucoderma, resident in Teresina (Piauí), presented the Urgency Clinic of the School of Dentistry of the Paulista University - FOUNIP São Paulo, sent by the São Paulo Hospital of the Federal Medical School UNIFESP), for diagnosis and treatment of intra and extraoral manifestations, accompanied by the mother. At the patient's first view, an extraoral fistula lesion was observed in the submandibular region of the left side. It was also evident the presence of alteration of volumetric increase in upper lip. In the anamnesis, the mother reported that her daughter from birth showed developmental delay, both general and psychological, and had respiratory difficulties since her birth, constant fevers, multiple and aggravated pictures of sinusitis, and continuous pneumonia. The mother sought medical attention when her daughter was 5 years old at the local Basic Health Unit where they prescribed an antibiotic, the type of which the mother could not specify, but reported having given amoxicillin indiscriminately to the age of 9 years. It was then that, due to a worsening of the clinical picture, the mother took her to a Hospital in Teresina - PI, where she underwent lung biopsy, and was referred to Hospital São Paulo.

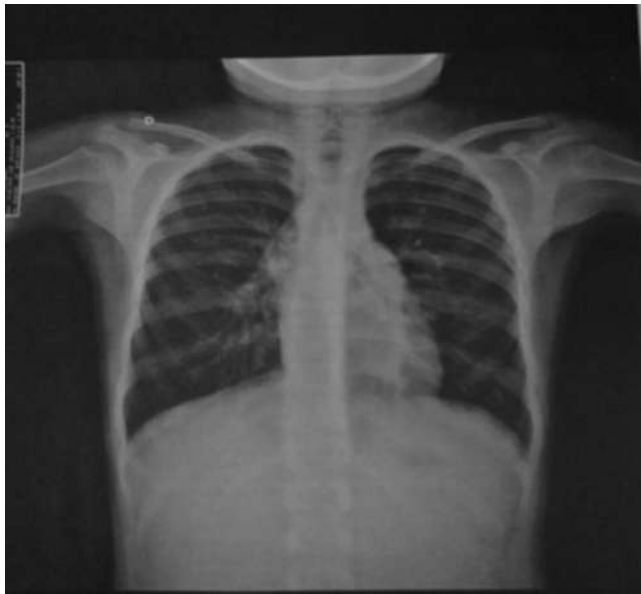
Received by the Hospital São Paulo, she underwent complementary examinations of cranio-podal computed tomography, chest X-ray (Fig. 2), analysis of pulmonary material collected again in São Paulo, also presenting dextrocardia, and closing the diagnosis of Kartagener Syndrome. At the CEAPE UNIP, anamnesis was performed, intra and extra oral clinical examination, teeth in poor hygiene conditions and decayed, an extra oral fistula in the cervix facial region draining purulent collection, a lesion that relapsed 4 times according to the patient's mother and volumetric increase in the upper lip quite evident. Panoramic X-ray and periapicalrx of element 36 were requested. Analyzing the panoramic radiograph (Fig. 1), disinfecting penetration of tooth 36, causing the fistula, was performed; and prescribing erythromycin 250mg 1 capsule every 8 hours for 7 days. Amoxicillin was not prescribed, since the patient had already developed resistance to it, due to prolonged and indiscriminate use in childhood. A drainage of the fistula was carried out, in which yellowish black secretion with fetid odor with characteristics of the sulfur granules compatible with actinomycosis was observed, strictly within the universal standards of biosafety. He also performed the incisional biopsy of the upper lip, and the material was sent to the laboratory of pathological anatomy where the material was processed, resulting in histopathological examination of orofacialgranulomatosis, and the conduct, in the first moment. The upper lip presented painless bilateral edema, with a 4-month evolution, in a roller shape with raised edges and



**Fig. 1. Panoramic radiography: tooth lesion 36**

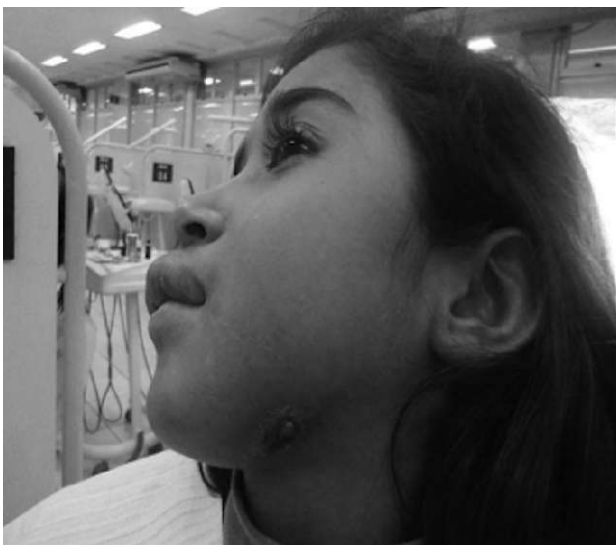


**Fig. 4. Periapical Rx: tooth 36 with lesion in the furcation region**



**Fig. 2. Chest radiography: dextrocardia**

fibrous consistency, besides having fissured areas, which caused discomfort to the patient. Its coloration was similar to that of the vermilion of the inferior lip (Fig. 3). The first diagnostic hypothesis was leishmaniasis, due to the region of origin, where the dwelling region is an endemic zone in Brazil. The Reaction from Montenegro test was then requested, which turned out to be negative.



**Fig. 3. Submandibular fistula and upper lip GC**

A discrete regression of the fistula was observed, and a periapical radiograph was taken (Fig. 4), where the presence of a 36-point tooth was observed, and the presence of a furcation lesion was observed, with the option of destroying the element 36, the exodontia of the fistula. In the oral cavity, there were numerous foci of intra-oral infections, such as residual roots of deciduous tooth 85, teeth 16, 54, 75 and 46 with deep caries, tooth 36 causing lesion of extra-oral fistula, and plaque index of 100 %. Guidance was given to oral hygiene, and its importance, using plaque-evident techniques with fuchsin for better visualization and awareness on the part of the mother and the patient. It was instructed in the method of brushing of Headphones, and the use of dental floss. Thus, besides providing a motivation for the patient, it was possible to obtain their collaboration and their confidence, as well as their conditioning, for the accomplishment of tooth extraction 36. This was performed under antibiotic prophylaxis with erythromycin 500mg 1 hour before, and by alveolar route. Precautions were taken regarding local anesthesia.

The use of mepivacaine without a vasoconstrictor was initially chosen because of bronchiectasis, but it was evaluated that it would be more detrimental to the patient if a large amount of anesthetic salt was administered, which could lead to toxicity with greater ease. Therefore, it was decided to use mepivacaine as an anesthetic with vasoconstrictor, providing greater patient comfort and reducing the possibility of toxicity. Antibiotic therapy was then prescribed with erythromycin 500mg for seven days, nimesulide 100mg for four days, and if in case of pain and necessary the lyser 25 drops every 6 hours. Successively performed procedures for the adaptation of the oral medium with glass ionomer and then the removal of caries and composite resin restorations of teeth 16, 75, and 46; extraction of decayed tooth 54, condemned by decay, and of the residual roots of tooth 85. The progressive involution of the fistula lesion (Fig. 5) was observed, but a deforming scar is still visible in view of the long duration of the fistula process and, with the removal of infectious foci showed a significant decrease in edema in the upper lip (Fig. 6). and in summary we can observe that eliminating the causes there was remission of the effects. Intraoral lip injections with corticosteroids were proposed for the treatment of the lip, but the family had an urgent need to return to Piauí, due to financial difficulty in staying out of the home, therefore, it was not possible to complete the treatment. The patient was treated with a physical therapist doing respiratory exercises, and followed up with psychology in that period, evidencing an expressive improvement in her self-esteem and in her communication, becoming more affable and with a great bond to the

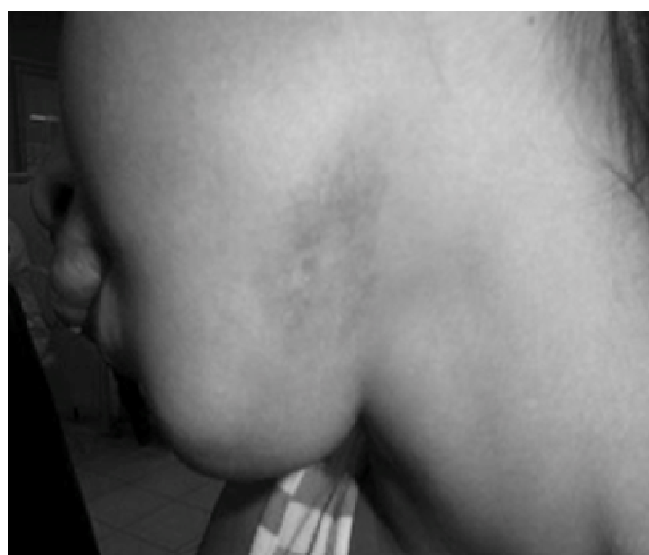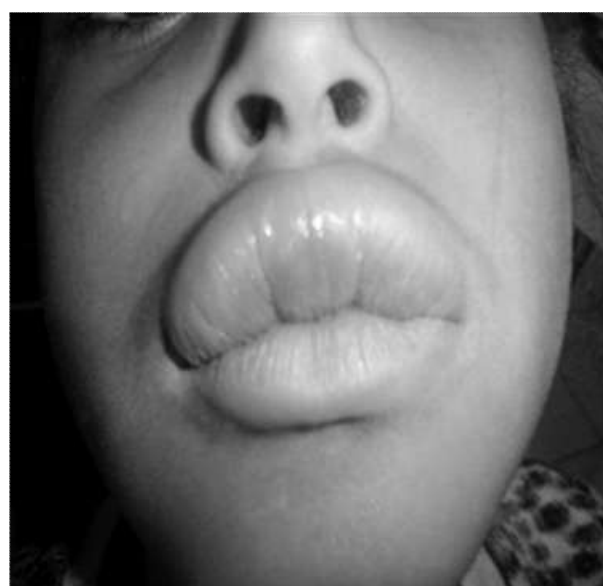

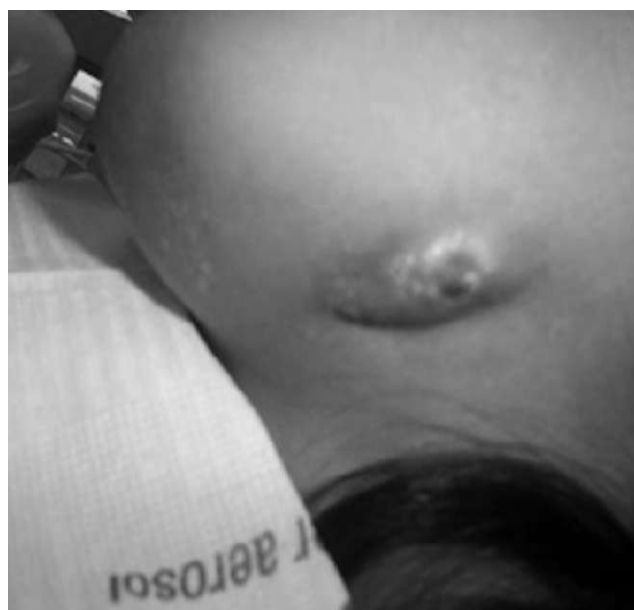
Fig. 5. Fistula lesion 1 and 3 weeks after exodontia of 36

professionals who treated her. Continuous control of the patient's systemic and oral situation in Piauí was recommended. It was observed, therefore, that the fistula completely regressed and lip edema regressed significantly after treatment of the patient's dental condition and removal of the infectious focus represented by the fistula.

## DISCUSSION

SK, and a rare disease characterized by the presence of the triad bronchiectas, situsinversus, sinusitis. It is caused by partial or total deficiency in the motility of cilia, especially the upper and lower cilia, but may affect sperm and decrease the motility of the uterine tubes, which can cause infertility in men and women respectively. Its signs and symptoms are difficult to diagnose, although they occur from the first months of life. In the neonatal period respiratory problems, pneumonia, rhinorrhea, and nasal obstruction are observed immediately after birth, as the mother of the patient reported in the anamnesis. During the school year, patients with KS present chronic purulent cough, rhinosinusitis, otitis media, pneumonia and bronchiectasis, being fully compatible with the patient's picture of this case report.

Fig. 6. GC on lip in first and last care

It is estimated that the majority of patients who demonstrate these symptoms undergo evaluation of several physicians before being diagnosed, with a delay of 10.9 to 14.4 years. (Tanaka *et al.*, 2012; Kurkowiak *et al.*, Behan *et al*). The patient, even presenting all these symptoms, was diagnosed only at 9 years of age. The early diagnosis of this syndrome is of fundamental importance, since they affect the lungs, essential organs to life. For this, there are advanced techniques such as the combination of lung and / or tracheal biopsy examined with electron microscopy. Another diagnostic method is based on the observation of the frequency of ciliary beats: in normality this frequency varies between 12 and 14 Hz; in patients with KS it is generally observed that the frequency decreases to 8 Hz, but in some cases it may be unchanged. This is why it is important to know other methods like the saccharin test. The mucous movement of the eyelashes transfers the saccharin present in the anterior part of the inferior turbinates to the oral fornix, which perceives it. In patients with KS this process lasts 60 minutes, while in healthy patients the time is around 20 minutes.



This test, however, is rarely used in children, as it requires it to stand still for an extended period of time, which is often not feasible. (Klysiak 2008, Bahan *et al* 2017). There is a test that calculates the nasal nitrogen monoxide (NO). Their normal values exceed 200nl / min in healthy subjects; but are less than 50nL / min in KS cases. However, in patients with normal ciliary mobility, this value is unchanged (Tamalet 2011, Lucas *et al* 2017). It can therefore be said that the most accurate test is electron microscopy. Granulomatous cheilitis has an unknown prevalence, but it can be considered present in 800 of every 100,000 people, occurring mainly in adolescents and young adults (McCartan *et al.*, 2011, Bent 2017). There is controversy regarding the classification of GC and on the one hand it is considered as the oral manifestation of a systemic condition such as Crohn's disease or Wegener's granulomatosis (Parag 2012; Chang *et al* 2017), characterized by the triad necrotizing granulomatous lesions, vasculitis and necrotizing glomerulonephritis (Lucas *et al.*, 2017); on the other hand, GC may be associated with several factors, since, historically, it is known that Merkelsson, in 1928, described a case of orofacial edema with facial paralysis; in 1932, Rosenthal defined the nomenclature Merkelsson-Rosenthal Syndrome (SMR) as the triad consisting of labial edema, fissured tongue, and recurrent facial paralysis. In 1945, Meischer determined granulomatous cheilitis as a variant of SMR, that is, only the presence of labial edema, without facial paralysis or fissured tongue.

Subsequently, in 1951, Sheingold and Shengold observed the presence of granulomas similar to those of GC in patients with tuberculosis. Later, in 1985, Weisenfeld correlated granulomas with sarcoidosis; and in 2000, Crohn associated oral and perioral granulomas with Crohn's disease. Finally, Wiesenfeld defined the term GC as representing orofacial granulomas and without any systemic diseases. (Parag 2012, Knowles *et al* 2014). It affects individuals of all ages, races, and geographic locations. It occurs in both genders, with a slight predilection for the female sex, since women appear to develop a much more exacerbated immune response than men (Gashem *et al* 2007, Raidt *et al* 2014). Its specific etiologic factor has not yet been discovered, but it may be related to oral hygiene products, such as dentifrices; dental materials such as amalgam; cocoa; cinnamon; artificial dyes, such as E122, E110, E621, E210-219, and E102; fungal infections, mainly by mycobacteria, and by sarcoidosis; and by immunosuppression. Histologically it is characterized by the presence of non-caseous granulomas, with or without multinucleated giant cells, lymphangiomas and perivascular lymphatic infiltration. However, in some cases, the only laboratory finding is a nonspecific inflammatory infiltrate. (McCartan *et al* 2011, Lucas *et al* 2017) Clinically, GC preferentially affects the lips, and the edema may be uni or bilateral. In some patients it may involve up to the eyelid region. In an oral examination, one can observe generalized edema, erythema, superficial ulcerations, and papules. Other features involve dysgeusia, hypo or hypersalivation. Remembering that when the disease is restricted only to the region of the lips it is called Miescher's GC. (Alawi 2005, Chang *et al* 2017). Treatments involve injections of triamcinolone acetonide; surgery that, however, is little accomplished, since it is mutilating, systemic corticosteroid therapy, or intralesional. (Parag 2012, Gupta *et al* 2012). There are studies that prove the efficacy of low-power laser therapy in cases of GC, but it should be considered that the spontaneous resolution of the lesion is very rare. (Alana *et al* 2010, Gupta *et al.*, 2012, Merigo *et al.*, 2012).

What we observed in the patient is that when the causes were eliminated the adverse effects regressed significantly.

## Conclusion

- SK and GC are rare diseases that have different but difficult to diagnose characteristics. In this case, resolution of the fistula process was observed due to the carious lesion of the tooth 36, an infectious process which, together with poor oral hygiene status and immunosuppression due to the patient's systemic situation, probably contributed to the formation of QG.
- The health professional must have in-depth knowledge about his techniques and methods of action, always with a view to the health of the patient. Therefore, it is fundamental to always carry out multiprofessional work, especially if the patient has an important systemic involvement.
- This case report highlights the importance of attending Dentist Surgery to the patient as a whole, without being restricted to the oral cavity alone.

## REFERENCES

- Alana, J., Tuxen, Orchard, D. 2010. Childhood and adolescent orofacialgranulomatosis is strongly associated with Crohn's disease and responds to intralesionalcorticosteriodes. *Australas J Dermatol.* May 51:2: 124-127
- Alawi, F. 2005. Granulomatous diseases of the oral tissues: differential diagnosis and update. *Dent Clin N Am., Jen]* 49:1:203-221
- Behan, L., Leigh, M.W., Dell, S.D., Dunn Galvin, A., Quittner A.L., Lucas, J.S. 2017. Validation of a health-related quality of life instrument for primary ciliary dyskinesia (QOL-PCD). *Thorax.* Sep;72(9):832-839.
- Bent, J.P., Oppenheimer, J.J. 2017. Primary Ciliary Dyskinesia (Kartagener Syndrome) *Drugs & Diseases - Pulmonology* Mar 03
- Bush, A., Chodhari, R., Collins, N., Copeland, F. Hall, P. Harcourt, J. *et al.* 2007. Primary ciliary dyskinesia: current state of art. *Arch Dis Child.*, Dec 92:12:1136-1140;
- Carlén, B. 2005. Primary ciliary dyskinesia: a review. *UltrastructPathol.*, 29: 217-220
- Chang, W.J., Kung, W.C., Chiu, W.Y. 2017. Kartagener syndrome. *QJM.* Aug 1;110(8):523.
- Ferkol, T.W., Leight, M.W. 2012. Ciliopathies: the central role of cilia in a spectrum of pediatric disorders. *J Pediatr March* 160:3: 366-371
- Ghasem Shams M., Hosein Kalantar Motamedi M., Azizi, T. 2007. Orofacialgranulomatosis of the lower lip and cheek:report of a case. *Surg Oral Med Pathol Oral Radiol Endod.*, 104:e42-e44
- Gupta, S., Handa, K.K., Kasliwal, R.R., Bajpai, P. 2012. A case of Kartagener's syndrome: Importance of early diagnosis and treatment. *Indian J Hum Genet.*, May 18:2: 263-267
- Jham, B.C., Meiller, T.F., King, M., Scheper, M.A. A diffuse but subtle swelling of the upper lip. *Oral Surg Oral Med Oral Pathol Oral Radiol Endodon.* 106:6:773-777;
- Klysiak M. 2008. Ciliary syndromes and treatment. *Pathol Res Pract.*, Feb 204:2:77-88
- Knowles, M.R., Ostrowski, L.E., Leigh, M.W. *et al.* 2014. Mutations in RSPH1 cause primary ciliary dyskinesia with

- a unique clinical and ciliary phenotype. *Am J Respir Crit Care Med.*, 189:707.
- Kurkowiak, M., Ziętkiewicz, E., Witt, M. 2015. Recent advances in primary ciliary dyskinesia genetics. *J Med Genet.*, 52:1.
- Lucas, J.S., Barbato, A., Collins, S.A. *et al.* 2017. European Respiratory Society guidelines for the diagnosis of primary ciliary dyskinesia. *Eur Respir J.*, 49.
- McCartan, B.E., Healy, C.M., McCreary, C.E., Flint, S.R., Rogers, S., Toner, M.E. 2011. Characteristics of patients with orofacialgranulomatosis. *Oral Dis.*, Oct; 17:7:696-704
- Merigo, E., Fornaini, C., Manfredi, M., Meleti, M., Alberici, F., Corcione, L. *et al.* 2012. Orofacialgranulomatosis treated with low-level laser therapy: a case report. *Oral Surg Oral Med Oral Pathol Oral Radiol* Jun 113:6:e25-e29
- Parag Rana, A. 2012. Orofacialgranulomatosis: a case report with review of literature. *J Indian Soc Periodontol.*, Jul 16:3:469-474
- Puri, H., Narans, V., Chawla, J. 2016. Actinomycosis of submandibular gland: An unusual presentation of a rare entity *J Oral Maxillofac Pathol.*, 19(1): 106.
- Raidt J, Wallmeier J, Hjejij R, *et al.* 2014. Ciliary beat pattern and frequency in genetic variants of primary ciliary dyskinesia. *Eur Respir J.*, 44:1579.
- Tamalet A. 2011. Dyskinésieciliarecongénitale: qui et comment explorer? *Arch Pediatr* Aug 18:8:921-925
- Tanaka T, Ogawa S, Nakatani K, Fujisawa T, Usui S, Masuda S. *et al.* 2012. Primary ciliary dyskinesia in two siblings. *Int J PedOtorhinolaryngol.*, March 7:2:59-63;

\*\*\*\*\*