



ISSN: 0976-3376

Available Online at <http://www.journalajst.com>

**ASIAN JOURNAL OF
SCIENCE AND TECHNOLOGY**

Asian Journal of Science and Technology
Vol. 08, Issue, 10, pp.6100-6105, October, 2017

RESEARCH ARTICLE

BRAIN TUMOR FEATURES GENERATION FROM MRI T2-WEIGHTED GRAYSCALE IMAGES USING PSEUDO COLOURING PROCESSES

***Kalaiselvi, T. and Kumarashankar, P.**

Department of Computer Science and Applications, The Gandhigram Rural Institute – Deemed University
Gandhigram, Tamilnadu - 624302

ARTICLE INFO

Article History:

Received 02nd July, 2017
Received in revised form
16th August, 2017
Accepted 21st September, 2017
Published online 17th October, 2017

Key words:

Intensity mapping,
Colour components,
Feature extraction,
Tumor segmentation,
MRI image.

ABSTRACT

In this paper, we generate two novel colour component features (ClrComFea) for brain tumor segmentation from MRI images. This feature extraction process is purely based on the knowledge of multimedia colour models and MRI brain tumor characteristics. Initially the original grayscale MRI brain images are converted into colour images using pseudo colouring process. Then the pseudo coloured brain images are analysed for tumor features based on the presence of colours within the tumor locations. This subject specific knowledge about the brain tumor and colour components is used to generate two ClrComFea. Finally these two extracted features are segmented and treated as brain tumor and necrotic regions respectively. Experimental study was done over a set of T2-weighted MRI images. The validation process by the proposed method results in good quality and quantitative measures.

Copyright©2017, Kalaiselvi and Kumarashankar. This is an open access article distributed under the Creative Commons Attribution License, which permits unrestricted use, distribution, and reproduction in any medium, provided the original work is properly cited.

INTRODUCTION

A brain tumor is a cluster of abnormal cells growing in the brain (Kalaiselvi, 2011). Primary brain tumors have origin and location in the brain. Metastatic brain tumors begin as cancer elsewhere in the body and migrate to the brain. The cause of brain tumors is unknown but they are treatable. Usually brain tumors have subsections: necrotic, active tumor, edema as shown in Fig.1 and Fig.2. They have necrotises, a form of death cells as tumor core. These necrotises are usually surrounded by active tumors. Edema, a form of fluid will be filled in-between and around these two regions (Kalaiselvi, 2011 and Somasundaram, 2010). Varieties of imaging techniques are used to diagnose the brain tumors. MRI is the most commonly used technique for brain tumor surgery planning process. Imaging intensity of tumors usually occupies the high end gray spectrum of T2-weighted MRI scans (Kalaiselvi, 2011). A sample axial oriented T2-weighted MRI brain tumor scan image along with the tumor subsections is given in Fig. 2. Tumor segmentation from magnetic resonance images (MRI) may aid in tumor treatment by tracking the progress of tumor growth and/or shrinkage (Kalaiselvi, 2011 and Somasundaram, 2010).

Numerous automatic methods for brain tumor detection and segmentation were developed. They are categorized as segmentation techniques: threshold based methods, regions based methods, clustering techniques: k-means, Fuzzy C Means (FCM) and classification techniques: support vector machines, self organization maps, artificial neural networks (Ananthi, 2015; Kalaiselvi, 2013). All these automatic methods depend on image based tumor characteristics. The accuracy of each method depends on the amount of knowledge used to define the tumor features and its boundaries (Kalaiselvi, 2015 and Kalaiselvi, 2012). The proposed work generates two novel colour component features (ClrComFea) for brain tumor and necrotic tissues segmentation. It is based on the knowledge of MRI brain tumor characteristics and multimedia colour models. Initially the gray scaled MRI brain images are converted into colour images. Then the pseudo coloured brain images are analysed for tumor features based on the presence of colours within the tumor locations. Finally these two extracted features are segmented and treated as brain tumor and necrotic regions respectively. Experimental study was done over a set of T2-weighted MRI images and produces good results. In this paper, Section 3 describes the popular multimedia colour models and their representations. Section 4 gives the proposed work for ClrComFea extraction and brain tumor segmentation. Section 5 discusses the results and section 5 concludes the proposed work.

***Corresponding author: Kumarashankar, P.**

Department of Computer Science and Applications, The Gandhigram Rural Institute – Deemed University, Gandhigram, Tamilnadu - 624302

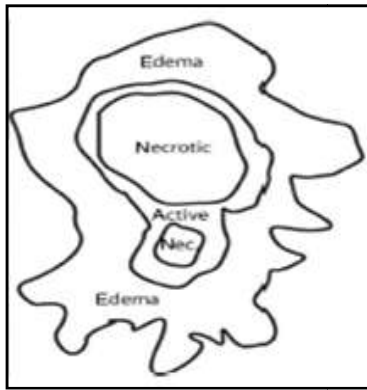


Figure 1. Sub-Regions of Brain Tumor

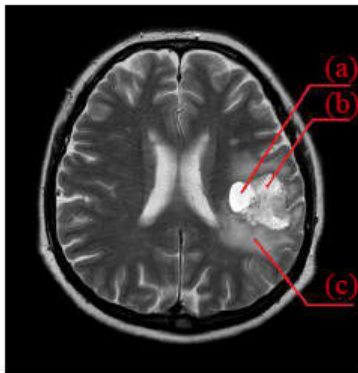


Figure 2. T2-weighted image showing the brain tumor. (a) Tumor. (b) Necrotic tissue. (c) Edema

MULTIMEDIA COLOUR MODELS

An important component in visual media and multimedia is colour. There is a wide range of colour models commonly used to describe colour on a computer monitor and on a printed page. Models of colour are methods by which colours are grouped for specific purposes (Holzaschlag, 2010). While far from the complete list, the major colour models used to describe colour within multimedia, computer graphics and image processing fields are: Bitmap, grayscale, RGB (Red-Green-Blue) CMYK (Cyan-Magenta-Yellow-black), HSV (Hue-Saturation-Value). The simplest of all the colour models is bitmap. Bitmap in terms of colour models refers to a model where there are only two possible values: black or white. This model is used to represent the binary images in terms of black and white values. This is mostly used in image processing field to generate the masks and shape analysis.



Figure 3. Grayscale

The grayscale colour model offers a tonal range of grays. In an 8-bit gray-colour model, grayscale has a pure black, a pure white and 254 shades of gray in-between as shown in the Fig.3. The grayscale format is best for images such as black and white photographs or any other image where a range of tonal variation between pure black and white is required. There are several established colour models used in computer graphics filed, but the three most common are the RGB,

CMYK and HSV. In RGB model, colours can be described by the combination of three primary colours Red, Green and Blue as shown in Fig.4. It is an additive colour model (meaning that red, green and blue light is ‘added’ together to form other colours) and popularly known as additive primaries. Each colour (red, green and blue) has a possible value of between 0 (no colour) and 255 (full colour) and are expressed in (R:0-255, G:0-255, B:0-255).

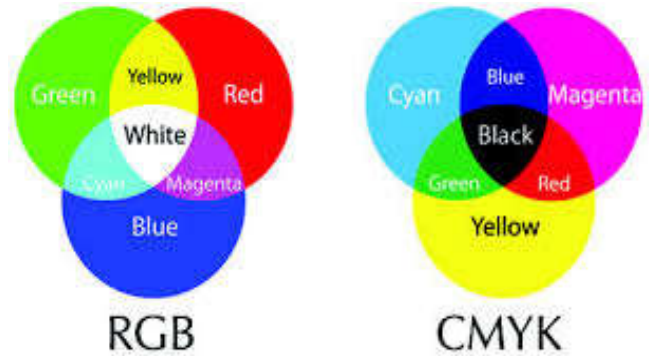


Figure 4. RGB and CMYK primaries

The CMYK model as shown in Fig. 4. is based upon the combination of four inks commonly used to print images. This is popularly called as subtractive primaries where colours are specified by what is subtracted from white light, rather than by what is added to blackness. A CMYK colour is represented with a series of four percentages corresponding to the four inks; for example, a sky blue colour would be: (C=60% Y=40% M=0% K=0%).

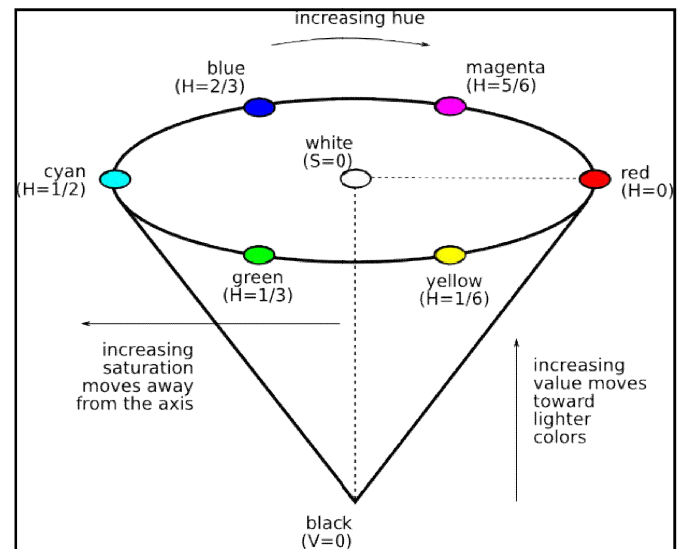


Figure 5. HSV Colour model

Hue, Saturation, Value or HSV is a colour model that describes colours (hue or tint) in terms of their shade (saturation or amount of gray) and their brightness (value or luminance) as shown in Fig.5. Because the HSL model keeps the light and saturation aspects of the colour model unique from each other, it tends to be more useful for those wishing to take advantage of these attributes in their work. The HSV colour wheel may be depicted as a cone or cylinder. Hue is expressed as a number from 0 to 360 degrees representing hues of red (starts at 0), yellow (starts at 60), green (starts at 120), cyan (starts at 180), blue (starts at 240), and magenta

(starts at 300). Saturation is the amount of gray (0% to 100%) in the colour. Value (or Brightness) works in conjunction with saturation and describes the brightness or intensity of the colour from 0% to 100%.

MATERIALS AND METHODS

The proposed work is aimed to generate two novel colour component features for the brain tumor and necrotic regions segmentation using pseudo colouring process. The gray coloured MRI images are given as inputs to this proposed method.

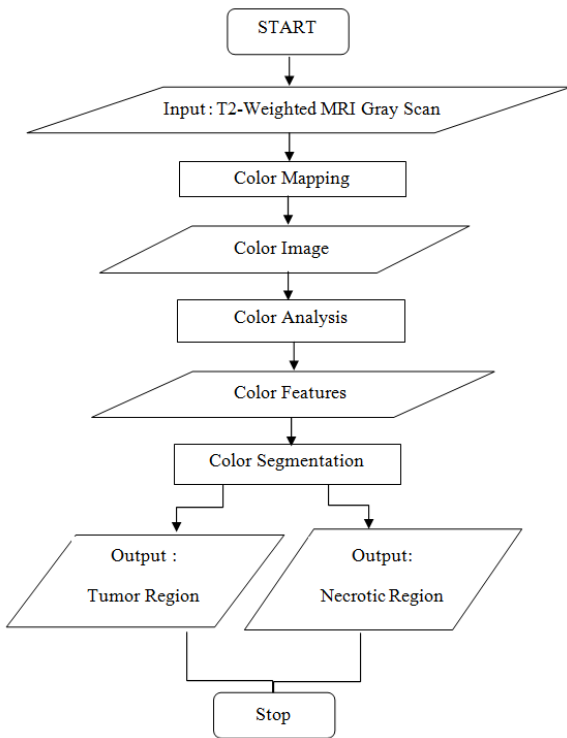


Figure 6. Flowchart of the proposed work

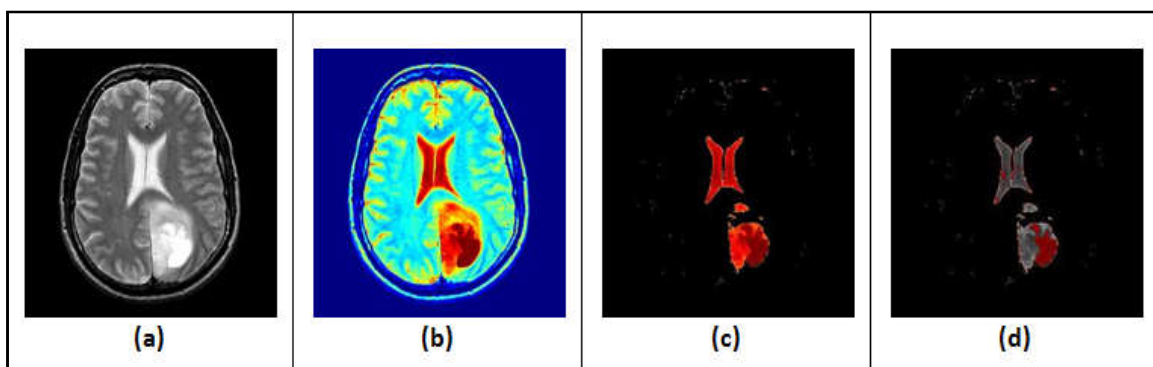


Figure 7. Results of proposed work (a) Original T2-weighted MRI Image (b) Colour converted image (c) Rust colour image for tumor region (d) Brown colour image for necrotic region

Two novel features based on colour component analysis are generated and used to estimate/predict the tumor regions and necrotic regions for the given image. The proposed work is a three step processes as given below and the flowchart is given in Fig.6.

Input: MRI T2-weighted grayscale image

Step 1: Colour Mapping

Step 2: Colour Analysis

Step 3: Colour Segmentation

Output: Tumor region and Necrotic region

Colour Mapping

Initially the gray coloured MRI input image is converted to RGB colour model using pseudo colouring process. The 8-bit gray image has 256 gray shades. Hence a colour function is invoked to convert the 256 gray shades into 256 colour values (Color conversion, 2013). In this function, a colour map corresponding to HSV model is used. The colours begin with dark blue, range through shades of blue, cyan, green, yellow and red, and end with dark red. The input gray image and its converted colour image are shown in Fig.7 (a) and Fig.7 (b).

Colour Analysis

In the colour image, the CSF and whole tumor regions are represented by yellowish and reddish cast colours. Hence these two colour shadings were targeted for locating the tumor regions. After doing careful analysis with the colours of each colour models, we found that rust colour is well suited for extracting whole tumor region.

Rust is a red-orange-brown colour resembling iron oxide. The word rust came from Germanic word, rusta, which translates to redness. The values used to represent the rust colour in each models are given below (www.wikipedia.com)

RGB(183,65,14) (1)

HSV(18,92%,72%) (2)

CMYK(22%,85%,100%,13%) (3)

Equation (1) and (3) proved the dominance of red and yellow colour in rust colour. The HSV model as given in equation (2) showed the brightness of rust colour is about to 72%. In T2-weighted MRI gray image, tumor and CSF have hyper-intense nature [2].

This proved that rust colour has relativity with tumor region in terms of the brightness factor also. Hence rust colour component is considered as a feature for whole tumor region extraction from a MRI slice. In the same way, brown colour is well suited for necrotic regions. The values used to represent the brown colour in each model are given below (www.wikipedia.com)

RGB(153,75,0) (4)

$$\text{HSV}(30,100\%,59\%) \dots\dots\dots(5)$$

$$\text{CMYK}(0\%,50\%,100\%,41\%) \dots\dots\dots(6)$$

Equation (4) and (6) proved the dominance of red and yellow colour in brown colour. The hue of HSV model also proved that brown has 30 degree in wheel colour that is half way between red (0 degree) and yellow (60 degree). The saturation is pure but little darkness is added with the colour. In MRI gray image, necrotic region is little higher hyper-intense nature than brain tumor region. Hence brown colour, a little higher end of the red, i.e., darkest red is considered as the feature to represent necrotic regions.

The above colour based analysis proved that the rust colour is used to represent the whole tumor region, and brown colour for necrotic regions.

$$\text{ClrComFea}(\text{Rust}) = \text{R}(\text{Whole Tumor}) \dots\dots\dots(7)$$

$$\text{ClrComFea}(\text{Brown}) = \text{R}(\text{Necrotic Tissues}) \dots\dots\dots(8)$$

These two colour based features are used to segment the respective regions from the given MRI tumor slices in the following step.

Colour Segmentation

This process is based on the VIBGYOR colour segmentation method (Kannan, 2008). In VIBGYOR method, the given RGB colour model image is separated into the seven colours based on some percentile combination of 3 planes and a colour filtering technique. This method is adopted to produce the rust colour and brown colour regions as shown in Fig.7(c) and Fig.7(d) and thus locating the brain tumor regions and necrotic regions respectively.

RESULTS AND DISCUSSION

For the validation process, the proposed method is tested for a few tumor volumes collected form the “whole brain atlas” website.

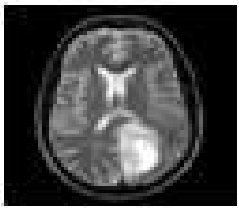
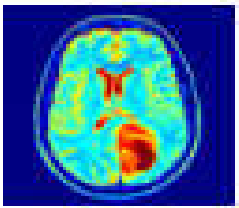
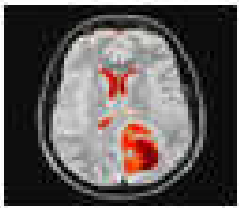


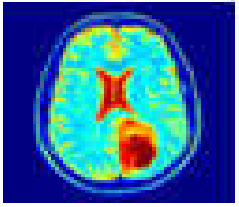
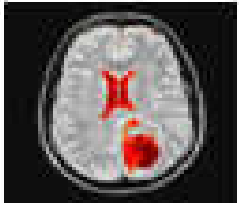


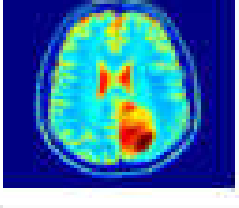
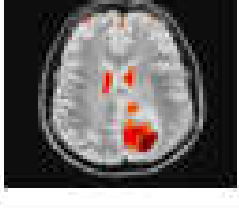


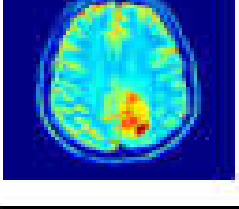
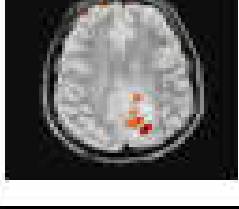

Original Gray Image	Color Image	Tumor Portion (R + Br + Or)	Necrotic (Br)
			
			
			
			

Figure 8. The original T2-w MRI gray images are in Column 1, the colour converted images are in Column 2, the whole tumor regions are in Column 3 and necrotic tissues regions are in Column 4

Table 1. For Outcomes

Manual Segmentation	Proposed Result	
	Tumor	Non-Tumor
Tumor	TP	FN
Non-Tumor	FP	TN

Table 2. Performance of Proposed Method in terms of Accuracy (A) and SI to tumor region detection

Volume Identity	Clinical Tumor type	Clinical			Tumorous Slices by Proposed Work	Validation Parameters					
		Total Slices	Tumorous Slices	Non Tumorous Slices		TP	FN	TN	FP	ACCURACY (A)	SI
3	Anaplastic Astrocytoma	56	25-45	0-13, 16-23	25-45	20	0	34	0	1	1
4	Astrocytoma	29	11-20	0-10, 21-28	11,13-18	7	3	19	0	0.8965	0.8235
6	Metastatic Bronchogenic Carcinoma	24	4-15	1-3, 16-23	6-14	9	3	12	0	0.875	0.857
8	Sarcoma	24	10-20	0-9, 21-23	11-16,18	7	4	13	0	0.833	0.777

The qualitative verification was done by visual inspection. The inputs and outputs of each step for some sample slices are given in Fig.8. The column 1 shows the original MRI gray images as inputs, column 2 shows the converted colour images, column 3 shows the rust colour component images corresponding to brain tumor related portions and column 4 shows the brown colour component images corresponds to necrotic regions. The qualitative analysis proved the exactness of the colour features with the regions of interests, here tumor region and necrotic region.

For the quantitative analysis, we used two parameters, named, accuracy (A) and similarity index (SI) as given below.

$$\text{Accuracy (A)} = (TP + TN) / (TP + TN + FP + FN) \dots\dots(9)$$

$$\text{Similarity Index (SI)} = 2TP / (2TP + FP + FN) \dots\dots(10)$$

where the values of the true positive (TP), false positive (FP), true negative (TN) and false negative (FN) are calculated as given in Table 1.

The values A and SI vary from 0 for complete disagreement to 1 for complete agreement between the manual segmentation and proposed work results. Four tumorous volumes were selected for quantitative validation and their clinical details are given in Table 2 (Somasundaram, 2010). These volumes were tested with our proposed work and the calculated values for tumor region detection were also listed in Table 2. Averagely, the proposed work attained 91 % accuracy (A) and 87% SI. The separation of necrotic regions from the tumor portion is the complex research area nowadays. Among the datasets, volume 4 has some necrotic regions and our proposed work detected them with the values of 83% to A and 67% to SI. The proposed work is simply doing this with the knowledge of colour models. The results show that these two features may play major roles in brain tumor classification techniques like support vector machine (SVM) and artificial neural networks (ANN). In future, it will be tested over a variety of tumor volumes. This will support to standardize the colour features, ClrComFea with a variety of intensity mapping techniques.

Conclusion

The proposed work generates two novel features based on colour components to extract the brain tumor and necrotic regions from the T2-weighted MRI brain images. Multimedia based colour models and their representations were analysed carefully with respect to tumor and necrotic characteristics. This colour based analysis produced two colour features to segment the brain tumor and its subsection necrotic. The visual quality is good for the proposed work. The quantitative results also show good accuracy and similarity with the clinical segmentation history. The efficiency of the proposed work will be improved by adding some statistical features, if needed.

REFERENCES

- Ananthi, V.P., Balasubramaniam, P., Kalaiselvi, T. 2015. "A new fuzzy clustering algorithm for the segmentation of brain tumor", *Soft Computing*, pp. 1-21, July.
- Colour Conversion by ind2rgb(), MATLAB R2013a.
- Holzschlag and E. Molly, 2010. "Colours for Website".
- Kalaiselvi, T. 2011. "Brain Portion Extraction and Brain Abnormality Detection from Magnetic Resonance Imaging of Human Head Scans" Pallavi Publications South India Pvt Ltd.
- Kalaiselvi, T., 2015. "Brain Tumor Image Repository (BTIR)", Department of Computer Science and Applications, The Gandhigram Rural Institute, Gandhigram.
- Kalaiselvi, T., Karthigai Selvi, S. 2013. "An Automatic Method to Locate Tumor from MRI Brain Images using Wavelet Packet Based Feature Set", LNAI 8284, pp. 173-179.
- Kalaiselvi, T., Kumarashankar, P. Sriramakrishnan, P. Nagaraja, P. 2015. "Novel Statistical Feature for Brain Abnormality Detection Process in Image Mines of MRI Head Volumes" *National Conference on Recent Advances in Computer Science and Applications*, pp. 119-123, March 2015.
- Kalaiselvi, T., Nagaraja, P. 2015. "A Rapid Automatic Brain Tumor Detection Method for MRI Images using Modified Minimum Error Thresholding Technique", *International Journal of Imaging Systems and Technology*, vol. 25, no. 1, pp. 77-85, March.

- Kalaiselvi, T., Somasundaram, K., Vijayalakshmi, S., 2012. "A Novel Self Initiating Brain Tumor Boundary Detection For MRI Images", International Conference on Mathematical Modelling and Scientific Computation – ICMMSC12, CCIS 283, Springer-Verlag Berlin Heidelberg 2012, pp. 464-470, March 2012.
- Kannan, K., Jeny Rajan, 2008. "VIBGYOR Colour Segmentation", Medical Imaging Research Group (MIRG), NeST, Trivandrum.
- Somasundaram, K. and Kalaiselvi, T. 2010. "Fully Automatic Method to Identify Abnormal MRI Head Scans using Fuzzy Segmentation and Fuzzy Symmetric Measure, *ICGST-GVIP Journal*, vol.10, no.3, pp. 1-9.
- Somasundaram, K., Kalaiselvi, T. 2010. "Automatic Detection of Brain Tumor from MRI Scans using Maxima Transform", UGC sponsored National Conference on Image Processing – NCIMP2010, vol. 1, pp. 136-141, February.
- www.wikipedia.com
