



ISSN: 0976-3376

Available Online at <http://www.journalajst.com>

ASIAN JOURNAL OF
SCIENCE AND TECHNOLOGY

Asian Journal of Science and Technology
Vol. 08, Issue, 09, pp.5417-5421, September, 2017

RESEARCH ARTICLE

ULTRASONOGRAPHY EVALUATION OF RENAL CYST DISEASE IN NNEWI URBAN, SOUTH EAST NIGERIA

¹Ugwuanyi Daniel, C., ^{1,*}Chiegwu Hyacinth, U., ²Anakwue Angel-Mary, C. and ¹Eze, E.K.

¹Department of Medical Radiography and Radiological Sciences, Nnamdi Azikiwe University,
Nnewi Campus, Anambra State, Nigeria

²Department of Medical Radiography and Radiological Sciences, University of Nigeria,
Enugu Campus, Enugu State, Nigeria

ARTICLE INFO

Article History:

Received 22nd June, 2017
Received in revised form
28th July, 2017
Accepted 12th August, 2017
Published online 15th September, 2017

Key words:

Ultrasound Evaluation,
Renal cyst disease,
Radiography Department,
Nnamdi Azikiwe University Teaching
Hospital Nnewi,
Waves diagnostics Nnewi.

ABSTRACT

Renal cysts were common findings in the kidneys encountered in daily routine ultrasound examination. The majority is benign, but they can become complicated in the case of infection, hemorrhage, and ischemia. Sonographic evaluation plays a great role in classification and characterization of these lesions. The aim of this study was to assess the occurrence of renal cyst, to assess the renal cysts and classify them according to the sonographic appearance and find relationship with age and sex in the study group. This is a retrospective cross-sectional study. A total of two hundred and ninety (290) ultrasound reports of adult patients that had been certified to have any form of renal cystic disease for a period of three year (June 2015- June 2017) in Nnamdi Azikiwe University Teaching Hospital and two diagnostic centers in Nnewi urban, Anambra State, Nigeria were used for the study. The demographic data were collected using a designed data collection sheet which included the symptoms, clinical history, and demographic information. Data were interpreted and analyzed using statistical package for social sciences (SPSS) software program version 21. The statistics was descriptive and data analysis was in line with the purpose of the study. The result showed that the incidence of renal cysts is significantly higher in male than female (64.8% vs. 35.2%, $P = 0.000$). Renal cysts were common in patients above 50 years old (63.1%). Aging was a significant factor of the renal cyst ($P = 0.000$) and size of the cysts was significantly associated with age ($P = 0.015$). The majority of cysts was solitary (76.6%), unilateral (86.5%), and more located in the right kidney (56.2%). The incidence of cortical simple renal cysts was 63.8%, para-pelvic simple renal cysts was 23.1%, autosomal-dominant polycystic kidney disease (ADPKD) was 10.3%, and acquired cystic kidney disease (ACKD) was 2.8%. The majority of simple renal cysts were asymptomatic (87.6%). Hypertension and flank pain were the common symptoms of ADPKD and ACKD. Age and gender were significant risk factors of renal cysts. ADPKD and ACKD were less frequent among Nnewi adults. Hypertension and flank pain were the most common signs and symptoms of ADPKD and ACKD. Ultrasound plays an effective role to classify and assess renal cysts that help in management and follow-up.

Copyright©2017, Ugwuanyi Danielet al. This is an open access article distributed under the Creative Commons Attribution License, which permits unrestricted use, distribution, and reproduction in any medium, provided the original work is properly cited.

INTRODUCTION

A renal cyst is a fluid collection in or on the kidney. Renal cysts, in general, may be classified as “simple” or “complex”. Simple renal cysts are best defined using sonographic criteria. These include: absence of internal echoes, posterior wall enhancement and oval shaped with thin smooth walls (Weber, 2006). When all the criteria are met the cyst is benign. The simple renal cysts are asymptomatic, but autosomal-dominant polycystic kidney disease (ADPKD) causes pain due to enlargement and hypertension which is one of the most

common early manifestations (Schrier, 2009). The difficulty arises when cysts do not meet the rigid characteristics of the “simple” definition. The development of renal cysts is extremely rare between birth and 20 years but thereafter, their prevalence increases progressively with age (Eknoyan, 2009). Other risk factors include male gender, renal dysfunction, and hypertension (Terada *et al.*, 2004). In all studies reported, renal cysts were more prevalent in men with reported male-to-female ratios of 4:1 (Carrim and Murchison, 2003) and 8:2 (Chang *et al.*, 2007). A large study of 29, 523 healthy adults (aged 40–88 years) who participated in a general health screening programme (including abdominal ultrasound or CT imaging) from South Korea confirmed a male-to-female ratio of 2.0-1.7 across each decade for the prevalence of renal cysts

*Corresponding author: Chiegwu Hyacinth, U.,
Department of Medical Radiography and Radiological Sciences,
Nnamdi Azikiwe University, Nnewi Campus, Anambra State, Nigeria

(Hong *et al.*, 2013). Autosomal-dominant polycystic kidney disease (ADPKD) is by far the most prevalent hereditary renal cystic disease and one of the most prevalent diseases in humans. Its prevalence ranges from 1 in 400 to one in 1000 individuals in white population. The corresponding figure in blacks is not yet available. In the 90s it represents only 5 to 7 percent of this because of the increasing number of elderly patients with diabetic and/or vascular renal diseases reaching end-stage (Pirson *et al.*, 1997). The ultimate diagnosis of many of the "cystic kidneys" requires clinical, genetic, radiological, and pathological information. Errors arise when insufficient information is gathered and collected. A precise diagnosis is important for prognosis, treatment, and genetic counseling although this may not be possible at presentation (Fick and Gabow, 1994). In some complex renal cystic diseases such as autosomal-dominant polycystic kidney disease, the diagnosis is primarily clinical. However, in presymptomatic patients with a family history of renal cysts, gene linkage laboratory analysis can be used in combination with sonography for screening (Avner and Sweeney, 2006). Moreover, the following imaging modalities can be used in diagnosing renal cysts. These include: magnetic resonance imaging (MRI) and computed tomography (CT). MRI has been widely used in the evaluation of cystic lesions in kidneys and other organs, usually with better performance than CT (Israel *et al.*, 2004). MRI better demonstrates the presence of thin septa in cystic lesions, in particular within cysts < 2.0 cm). Yet, because of artifacts inherent to MR imaging, septa in renal cystic lesions may appear thicker than on CT (Weibl *et al.*, 2011). The enhancement of thin septa, described as capillary or hair-like enhancement, is much more conspicuous at MRI than at CT. This provides greater confidence in their detection and for denying the absence of contrast-enhancement. Other advantage of MRI is the identification of contrast-enhancement of internal septa within hemorrhagic cysts (Kim *et al.*, 2012). The high density of blood hinders the perception of contrast enhancement on CT, but subtraction techniques on MR imaging can bypass this situation.

The use of ultrasound (US) in the Bosniak classification has never been unquestionably accepted, as the detection of neovascularization in malignant lesions, indicated by contrast enhancement of solid components, septa or walls, is a fundamental part of the classification (Ascenti *et al.*, 2007). However, it is known that US may demonstrate internal septa better than CT and even MRI (McGuire and Fitzpatrick, 2010). Another potential advantage of US is its capacity of defining the cystic or solid nature of the lesion. In some situations, the characterization of remarkably hypovascular lesions may be difficult on CT (Vikram and Tamboli, 2009). US can accurately indicate their degree of complexity and is an excellent method for the initial evaluation of patients with renal cystic lesions. Detection and assessment of renal cysts are necessary since there are asymptomatic patients who are involved with autosomal-dominant polycystic kidney disease and other acquired cystic diseases which develop silently and may result in renal failure and hypertension. Early detection and treatment of hypertension in autosomal-dominant polycystic kidney disease are very important since cardiac disease and renal failure are common cause of death (Peter and Vicente, 2015). In this locality under study, there is limited literature available about ultrasound evaluation of renal cyst to the best of the researcher's knowledge. Thus, the need to know the prevalence of renal cysts in our locality. This study

assessed the prevalence of renal cysts and classified them according to the sonographic appearance. It also evaluated the relationship of renal cyst with age and sex in the study population.

Objectives of the study

- To assess the occurrence of renal cyst in Nnewi urban of Anambra State.
- To assess the renal cysts and classify them according to the sonographic appearance and find relationship with age and sex in the study group.

MATERIALS AND METHODS

Research design

The study was a retrospective cross-sectional study, and ultrasonography reports of patients who had gone through abdominal ultrasound scan with cystic renal disease were used for the study.

Study population

Sampling Procedure

The sample size was calculated using the Taro Yamani formula (2011):

$$n = \frac{N}{1 + N(e)^2} \quad e = 5\%; \quad CL = 95\%; \quad n = ?$$

Where n = desired sample size

N = population under study, e = acceptable limit of error, 1 = a constant

$$\begin{aligned} n &= \frac{660 + 200 + 200}{1 + 660 + 200 + 200(0.05)^2} \\ &= \frac{1060}{1 + 1060(0.0025)} = \frac{1060}{1 + 2.65} \\ &= \frac{1060}{3.65} = 290 \end{aligned}$$

For this study, two hundred and ninety (290) ultrasound reports of adult patients that had been certified to have any form of renal cystic disease by a qualified sonographer or consultant radiologist for a period of three year in Nnamdi Azikiwe University Teaching Hospital and two diagnostic centers in Nnewi urban, Anambra State, Nigeria was used for the study.

Data Collection

Diagnostic ultrasound reports from the archive of the selected centers.

- Access of ultrasound archive and visual analysis of ultrasound information.
- The demographic data was collected using a designed data collection sheet which included the following: the symptoms, clinical history, and demographic information.

Every report that was used contained transverse and longitudinal diameters (in centimeter) to calculate the depth, length, and antero-posterior diameter. From these three measurements, the size of the cyst was estimated using the formula (Caroli *et al.*, 2013).

$$\text{Depth (D)} \times \text{Length (L)} \times \text{Width (W)} \times 0.5$$

- The reference of sonographic criteria for differential diagnosis of autosomal-dominant polycystic kidney disease were as follows: (Ravine *et al.*, 1994)
 - Existence of at least two cysts in one kidney or one cyst in each kidney in patient's reports younger than 30 years
 - Existence of at least two cysts in each kidney in patient's reports aged 30–59 years.
 - Existence of at least four cysts in each kidney in patient's reports aged 60 years or older.

Analytical Procedure

The data collected was analyzed using statistical package for social sciences (SPSS) software program version 21 (SPSS, Inc., Chicago, IL, USA). Descriptive statistics and nonparametric test was used to analyze the variables. Chi-square test was applied to obtain the significance between age and size of renal cysts. Level of significance was set at 95% confidence level and $P < 0.05$ was considered statistically significant.

RESULTS

This chapter was based on the available data collected from two hundred and ninety (290) adult patient's ultrasound reports. These reports were certified to have different types of renal cystic disease by a qualified sonographer or consultant radiologist. The data were collected from Nnamdi Azikiwe University Teaching Hospital and two private diagnostic centers in Nnewi urban, Anambra State, Nigeria. The results were presented with tables and bar chart. The age range is between 20 years and above. The ages were categorized closely in order not to exclude any patient report that is expected to be included in the work. The age group was categorized into three groups, which include: 20-40 years, 40-50 years and >50 years old.

Table 1. Gender of the study population

Sex	Frequency	Percent	p-value
Male	188	64.8	0.000
Female	102	35.2	
Total	290	100.0	

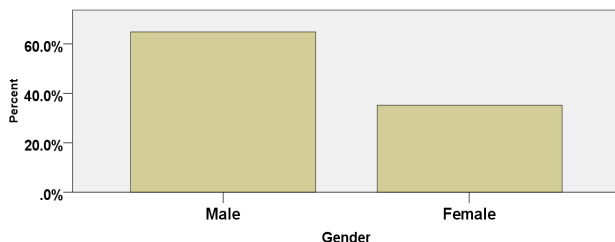


Fig. 1. Gender of the study population

Table 1/Figure 1 above show the distribution of gender and it was observed that male was significantly higher than female.

Table 2. Age (years) distribution of the study population in relation with renal cysts

Age groups(years)	Frequency (%)	Mean Age (years)	p-value
20-40	47(16.2)	41±2	0.000
40-50	60(20.7)		
>50	183(63.1)		
Total	290(100.0)		

Table 2 above show the age group which are categorized into three groups and most of the patients were above 50 years old. The mean age of the study population is 41 years.

Table 3. Frequency distribution of location and Numbers of renal cysts

location of cysts	Frequency (%)
Right Kidney	163(56.2%)
Left Kidney	88(30.3%)
Bilateral	39(13.4%)
Unilateral	251(86.5%)
Number of cysts	
Solitary	222(76.6%)
Multiple	68(23.5%)

Table 3 above summarized most of the study variables such as site, and number of the cysts. The common site of the cysts was the right kidney (56.2%) and the left was 30.3%. The majority of renal cysts were solitary (76.6%) whereas 23.5% were multiple. Most of the renal cysts were located unilateral (86.5%) and bilateral was 13.4%.

Table 4. Classification of renal cysts among the study population

Group	Frequency (%)
Cortical simple cysts	185(63.8%)
Para-pelvic simple cysts	67(23.1%)
Acquired Kidney cystic disease	8(2.8%)
Autosomal-dominant polycystic kidney disease	30(10.3%)
Total	290(100%)

Table 4 above show the types of renal cysts. It was observed that simple cysts (cortical and para-pelvic) were the most common type which had been detected (63.8% cortical and 23.1% para-pelvic). Hence, the total number of simple cysts was 86.9% among the study population. The incidence of ADPKD was 10.3% and also the AKCD was 2.8%; they were less frequently common.

Table 5. Analysis of relationship between age (years) and size of the renal cysts (cm)

size of cysts	AGE				Pearson Chi-square value (p-value)
	20-40 years	40-50 years	>50 years	Total	
<3cm	30(10.34)	33(11.38)	85(29.31)	148(51.03)	12.307(0.015)
3-8cm	15(5.17)	19(6.55)	89(30.69)	123(42.41)	
8-13cm	2(0.69)	8(2.76)	9(3.10)	19(6.55)	
Total	47(16.21)	60(20.69)	183(63.10)	290(100.00)	

Table 5 above shows the association between age and size of the renal cysts. The largest size was observed in the age group above 50 years old (3.10%). The P value was 1.50% (0.015).

Table 6. Distribution of symptom and Signs of renal cysts in the study population

Symptoms and signs	Frequency (%)
Flank Pain	13(4.5%)
Hematuria	4(1.4%)
Hypertension	14(4.8%)
Dysuria	5(1.7%)
Asymptomatic	254(87.6%)
Total	290(100.0%)

Table 6 above summarized the symptoms of renal cysts. Most of the patients were asymptomatic 254(87.6%); hypertension 14(4.8%), flank pain 13(4.5%), dysuria 5(1.7%), and hematuria was present in only four cases 4(1.4%).

DISCUSSION

In this study, we used ultrasound reports to assess the renal cysts and classify them relying on the sonographic appearance. Detection of renal cysts is very important in health since it helps to prevent progression of renal failure and useful in differential diagnosis of renal cancer. For instance, autosomal-dominant polycystic kidney disease (ADPK) slowly progresses and results in the end stage of renal disease and has no effective therapy (Bakker *et al.*, 1998). In the previous studies, the prevalence of simple renal cysts was strongly associated with papillary renal cell cancer (Bakker *et al.*, 1999). The results of this study showed that the incidence of simple cysts was common in patients above 50 years old, (63.1%) and there was a significant relation ($P = 0.000$). This result is consistent with Chang *et al.*, (2007) who studied the prevalence and clinical characteristics of the simple renal cyst. He reported that the overall prevalence of simple renal cysts was common in the seventh or later decade of life and the prevalence increased with age ($P < 0.001$). This indicates that advancing age is a risk factor of renal cysts. This present study revealed that renal cysts were common in male than female (64.8% vs. 35.2%). This result is also agreed with Chang *et al.*, (2007) who found that male-to-female ratio was 8:2 (15.14% vs. 5.38%; $P < 0.001$). Ozveren *et al.*, (2016) concluded that renal cysts were more common in males and elders, and associated with diabetes. This finding confirms that gender is significantly associated with the prevalence of simple renal cysts. This present study showed that the renal simple cysts aroused from the cortex than the pelvis (63.8% vs. 23.1%). We observed that the renal cysts involved the right kidney than the left kidney (56.2% vs. 30.3%); and the incidence of bilateral is lesser than unilateral (13.4% vs. 86.5%). In literature and previous studies, we discovered no explanation demonstrating these findings.

A study performed by Ravine *et al.*, (1993) who studied the prevalence of renal cyst using ultrasound; he reported that bilateral cysts with one or both kidneys are relatively uncommon in the younger age groups. This current study revealed that the incidence of solitary cysts were more common than multiple cysts (76.6% vs. 23.5%). This finding agreed with a study conducted by Chang *et al.*, (2007) who reported that the majority of renal cysts were solitary (82.3%). In this current study, the size of renal cysts was measured and compared with age. The cysts were gradually increased in size as the age advancing. This current study observed that the largest cysts (8–13 cm) were present in patients above 50 years old and cysts lesser than 3 cm were common in 20–40 years old. There is significant association between the size of renal cysts and age ($P = 0.015$), these findings were generally agreed with Terada *et al.*, (2002) who concluded that the majority of renal cysts increased in size and number with age. Also, in this present study, we analyzed the frequency of symptoms of renal cysts. It was noted that the incidence of autosomal-dominant polycystic kidney disease (ADPKD) and acquired cystic kidney disease (ACKD) was 10.3% and 2.8%, respectively. The clinical importance of these cysts are that they cause hypertension and flank pain which is a common feature in patients with ADPKD and is difficult to control and manage (Tellman *et al.*, 2015). Miskulin *et al.*, (2014) studied health-related quality of life in patients with ADPKD and acquired cystic kidney disease (ACKD) stages, and concluded that pain is an early common

symptom in the course of ADPKD. This result is agreed with the finding of this current research that pain was the main symptom. The pain is attributed to the expansion of the cysts and enlargement of the kidneys which led to severe flank pain. Hypertension in ADPKD was studied by Chapman *et al.*, (2010) who reported that hypertension is a common symptom and occurs in a majority of ADPKD and relates to progressive enlargement of the kidneys. In this current study, hypertension is mainly attributed to ADPKD. In previous studies, relationship existed between renal cysts and hypertension. Hong *et al.*, (2013) assessed the impact of simple renal cysts on hypertension and evaluated the prevalence of these cysts and their relation with hypertension. They concluded that number of cysts, size, and location are important features related to hypertension. There were other diseases associated with simple renal cysts. Recent studies established an association of simple renal cysts with abdominal aortic aneurysm and aortic dissection (Ziganshin *et al.*, 2016). Hence, sonographic characterization of renal cysts is necessary, and ultrasound should be used as diagnostic tool to screen the population to control hypertension and pain. This will improve health-related quality of life, especially in patients with ADPKD and ACKD.

Conclusion

Simple cysts were more common than other types of renal cysts, and the majority arose from the renal cortex. The incidence of simple solitary cysts was higher than multiple cysts, and the prevalence of renal cysts was higher in male than female. The autosomal-dominant polycystic kidney disease (ADPKD) and acquired cystic kidney disease (ACKD) were less common in Nnewi community adults. Age and gender were common risk factors associated with renal cysts.

REFERENCES

- Ascenti, G., Mazziotti, S., and Zimbaro, G. 2007. Complex cystic renal masses: characterization with contrast-enhanced ultrasound. *Radiology*, 243:158–165.
- Avner, E.D., and Sweeney, W.E. 2006. Renal cystic disease: New insight for the clinician pediatric clinical North America, 53 (5):889-909.
- Bakker, J., Olree, M., Kaatee, R., De Lange, E.E., and Beek, F.J. 1998. *In vitro* measurement of kidney size: Comparison of ultrasonography and MRI. *Ultrasound Medical Biology*, 24:683-688.
- Bakker, J., Olree, M., Kaatee, R., De Lange, E.E., Moons, K.G., and Beutler, J.J. 1999. Renal volume measurements: Accuracy and repeatability of US compared with that of MR imaging. *Radiology*, 211:623-628.
- Carrim, Z.I., and Murchion, J.T. 2003. The prevalence of simple renal and hepatic
- Chang, C.C., Kuo, J.Y., Chan, W.L., Chen, K.K., and Chang L.S. 2007. Prevalence and clinical characteristics of simple renal cyst. *Journal Chinese Medical Association* 70:486-491.
- Chapman, A.B., Stepniakowski, K., and Rahbari-Oskoui, F. 2010. Hypertension in autosomal- dominant polycystic kidney disease. *Advanced Chronic Kidney Disease*; 17:153-163.
- Cysts detected by spiral computed tomography. *Clinical Radiology*; 58:626-629.

- Eknoyan, G. 2009. A clinical view of simple and complex renal cysts. *Journal American Society Nephrology*; 20:1874–1876.
- Fick, G.M., and Gabow, P.A. 1994. Hyperechoic kidneys in the newborn and young Infant. *Pediatric Nephrology*, 7:294–302.
- Hong, S., Lim, J.H., Jeong, I., Choe, J., Kim, C.S., and Hong, J.H. 2013. What association exists between hypertension and simple renal cyst in a screened population? *Journal Human Hypertension*; 27:539–544.
- Israel, G.M., Hindman, N., and Bosniak, M.A. 2004. Evaluation of cystic renal masses: comparison of CT and MR imaging by using the Bosniak classification system. *Radiology*, 231:365–371.
- Kim, W.B., Lee, S.W., and Doo, S.W. 2012. Category migration of renal cystic masses with use of gadolinium-enhanced magnetic resonance imaging. *Korean Journal Urology*, 53:573–576.
- McGuire, B.B., and Fitzpatrick, J.M. 2010. The diagnosis and management of complex renal cysts. *Current Opinion Urology*, 20:349–354.
- Miskulin, D.C., Abebe, K.Z., Chapman, A.B., Perrone RD, Steinman, T.I., and Torres Mojibian, VE, *et al.* 2014. Health-related quality of life in patients with autosomal-dominant polycystic kidney disease and CKD stages 1-4: A cross-sectional study. *American Journal Kidney Disease*, 63:214-226.
- Ozveren, B., Onganer, E. and Türkeri, L.N. 2016. Simple renal cysts: Prevalence, associated risk factors and follow-up in a health screening cohort. *Urology Journal*, 13: 2569-2575.
- Peter, C. and Vicente, E. 2015. Polycystic Kidney Disease, Autosomal-dominant. Available from: <http://www.ncbi.nlm.nih.gov/books/NBK1246>.
- Pirson, Y., Chauveau, D., and Grunfeld, J.F. 1997. Autosomal-dominant polycystic Kidney disease, in *Oxford Textbook of Clinical Nephrology*. A.M. Davison *et al.*, editor, 2nd Edition; Oxford University Press: (in press).
- Ravine, D., Gibson, R.N., Donlan, J., and Sheffield, L.J. 1993. An ultrasound renal cyst Prevalence survey: Specificity data for inherited renal cystic diseases. *American Journal Kidney Disease*, 22:803-807.
- Ravine, D., Gibson, R.N., Walker, R.G., Sheffield, L.J., Kincaid-Smith, P., and Danks, D.M. 1994. Evaluation of ultrasonographic diagnostic criteria for autosomal-dominant polycystic kidney disease 1. *Lancet*; 343:824-827.
- Schrier, R.W. 2009. Renal volume, renin-angiotensin-aldosterone system, hypertension, and left ventricular hypertrophy in patients with autosomal-dominant polycystic kidney disease. *Journal American Society Nephrology*, 20:1888-1893.
- Tellman, M.W., Bahler, C.D., Shumate, A.M., Bacallao, R.L., and Sundaram, C.P. 2015. Management of pain in autosomal-dominant polycystic kidney disease and anatomy of renal *international Journal Urology*, 193:1470-1478.
- Terada, N., Arai, Y., Kinukawa, N., Yoshimura, K., and Terai A. 2004. Risk factors for renal cysts. *BJU International*; 93:1300-1302.
- Terada, N., Ichioka, K., Matsuta, Y., Okubo, K., Yoshimura, K., and Arai, Y. 2002. The natural history of simple renal cysts. *Journal Urology*, 167:21-23.
- Vikram, R., Ng, C.S., Tamboli, P., Tannir, N.M., Jonasch, E., Matin, S.F., Wood, C.G., and Sandler, C.M. 2009. Papillary renal cell carcinoma: radiologic-pathologic correlation and spectrum of disease. *Radiographics*, 29:741–754.
- Weber, T.M. 2006. Sonography of benign renal cystic disease. *Ultrasound Clinics*, 1: 15–24.
- Weibl, P., Klatte, T., and Kollarik, B. 2011. Interpersonal variability and present diagnostic dilemmas in Bosniak classification system. *Scand Journal Urology Nephrology*, 45:239–244.
- Ziganshin, B.A., Theodoropoulos, P., Salloum, M.N., Zaza, K.J., Tranquilli, M., and H.R. 2016. *et al.* Simple renal cysts as markers of thoracic aortic disease. *Journal American Heart Association*; 5. pii: E002248.
