



ISSN: 0976-3376

Available Online at <http://www.journalajst.com>

ASIAN JOURNAL OF  
SCIENCE AND TECHNOLOGY

Asian Journal of Science and Technology  
Vol. 08, Issue, 01, pp.4147-4148, January, 2017

## RESEARCH ARTICLE

### SEBORRHEIC KERATOSIS – A CLINICAL CASE

\*Tsvetan Tsvetanov

Department of Oral Surgery, Dental Faculty, Medical University-Plovdiv, Bulgaria

#### ARTICLE INFO

##### Article History:

Received 07<sup>th</sup> October, 2016  
Received in revised form  
20<sup>th</sup> November, 2016  
Accepted 28<sup>th</sup> December, 2016  
Published online 31<sup>st</sup> January, 2017

##### Key words:

Excision, Pigmentation,  
Seborrheic keratoses.

Copyright©2017, Tsvetan Tsvetanov. This is an open access article distributed under the Creative Commons Attribution License, which permits unrestricted use, distribution, and reproduction in any medium, provided the original work is properly cited.

#### ABSTRACT

The aim of this case report is to review a case of a patients with seborrheic keratoses pigmented type. Clinical examination of the right extraoral site revealed a single, well-defined brownish nodular mass situated by 1.5 cm below the right pinna, near the mandibular angle and close to the sternocleidomastoid muscle. The treatment include extraoral excision and histopathological examination. The postoperative period was without complications.

#### INTRODUCTION

According to R. G. S. Phulari *et al.*, 2014 seborrheic keratoses are common, benign, pigmented epidermal tumors. Many terms such as senile wart, melanoacanthoma, basal cell papilloma, senile keratosis and seborrheic wart have been applied, but seborrheic keratosis is the most widely accepted term. The authors described clinical case of a 67-year-old Indian female with the chief complaint of a painless mass below the left ear since last 15 years. The lesion showed slow growth and the patient reported no increase in size for past many years. Seborrheic keratoses is commonly seen in the head and neck region, but it rarely causes functional impairment.

When it is present at the external auditory canal, it can cause conductive hearing loss, which needs to be corrected by excision (B. S. Girisha *et al.*, 2012). P. Rajabi *et al.*, 2012 studied 429 seborrheic keratosis cases that underwent excisional biopsy and revealed 6 (1.4%) lesions associated with malignant transformation among which five cases showed bowenoid transformation and one revealed mild dysplasia in squamous epithelium. Z. H. Bhuiyan, 2007 described treatment of patient with seborrheic keratosis with Liquid nitrogen (Cryosurgery) and Electrofulguration (Electro surgery) in six sessions with the interval of 15 days.

\*Corresponding author: Tsvetan Tsvetanov

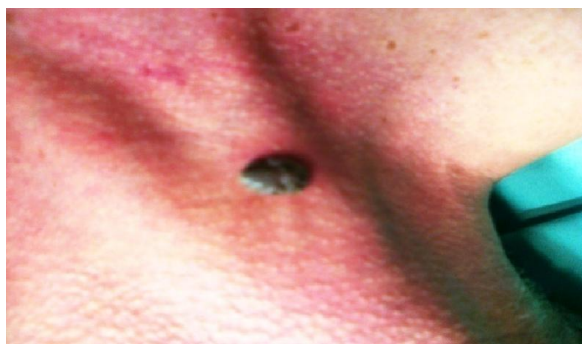
Department of Oral Surgery, Dental Faculty, Medical University-Plovdiv, Bulgaria.

#### CASE REPORT

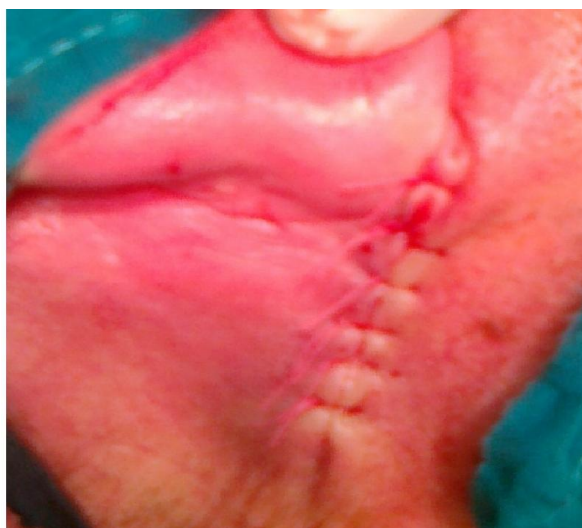A 71-year-old Bulgarian female presented with the chief complaint of a painless mass below the right ear since last 9 years. The lesion showed slow growth and the patient reported no increase in size for past many years. Clinical examination revealed a single, well-defined brownish nodular mass with approximately 1.5 cm size under the right ear in front of the sternocleidomastoid muscle. The pedunculated mass measured about 1.5 × 1.5 cm and the overlying skin was rough and fissured with nodular surface projections (Fig 1). On palpation, the mass was firm in consistency with no pain. The woman was undergo local anesthesia (local infiltration). The pigmented epidermal tumors was excised with raised a flap. Hemostasis was performed. The surgical site are closed with single interrupted non-absorbable sutures. Postsurgical instructions were given to the patient and he was kept on analgesic coverage. Patient was instructed to keep a good hygiene to prevent postoperative infection. The patient is on follow-up for 1 week following. The postoperative period was without complications (Fig 2). Histopathological examination revealed basal cell papilloma containing melanin pigment.

#### DISCUSSION

Seborrheic keratosis is one of the most common benign neoplasms in adults. Seborrheic keratoses begin to appear after the age of 30 years in genetically susceptible individuals and continue to develop throughout their life span (L. Izikson *et al.*, 2002). According to O. S. Kwon *et al.*, 2003 seborrheic keratoses is a major pigmentary problem.



**Fig. 1. Well-defined brownish nodular mass**



**Fig. 2. Postoperative healing process**

Both aging and cumulative sunlight exposure were found to be independent contributory factors. Different from us K. K. Luen *et al.*, 2016 reported unusually large sizes of seborrheic keratosis - patient was a 75-year-old male with no known medical illnesses who had a large, painless, pedunculated lesion on the right side of his face for the past 30 years. Clinically, there was a 20 × 15 cm oval-shaped pedunculated lesion, which appeared with an uneven surface and verrucous-like at the right temple, pulling down the right lateral upper eyelid, firm in consistency, mobile and with a well-demarcated stalk at the base. The development of basal cell carcinoma (BCC) in seborrheic keratosis (SK) is rare. Review of over 10,000 biopsies from SK revealed fourteen cases (Mikhail and Mehregan, 1982). Dermatopathology is the practice of assessing cutaneous diseases at the cellular level by performing microscopic examination of skin biopsy tissue samples. Histologic examination is a valuable diagnostic tool, frequently affecting treatment decisions (Chung *et al.*, 2015). Basal cell papilloma containing melanin pigment producing macroscopically visible warty projections from epithelial surfaces. Commonly papilloma derived from the basal cells. According to K. J. Busam, 2010 pigmented subtype may be clinically confused with other pigmented lesions, such as malignant melanoma and melanocytic nevus.

Cryosurgery is the most common removal method. Other commonly employed removal methods include shave excision, electrodesiccation, curettage or a combination (Jackson *et al.*, 2015).

### Conclusion

In medicine, early detection and accurate diagnosis of the seborrheic keratoses is of paramount importance for successful treatment. Therefore, the doctor must have knowledge of the biological and histological behavior of seborrheic keratoses and her frequency to ensure early detection, accurate diagnosis and proper treatment.

### REFERENCES

- Bhuiyan, Z. H. 2007. Seborrheic Keratosis: A case report, *The ORION Medical Journal*, pp. 441-442.
- Busam, K. J. 2010. A volume in the series foundation in diagnostic pathology Philadelphia: Elsevier; *Dermatopathology*, 1st ed., pp. 336-343.
- Chung, Y. Grace, Morrell, J. Travis, Kerstetter, and Justin 2015. Seborrheic Keratosis, *Journal of the Dermatology Nurses' Association*, Vol. 7, № 6, pp. 359-361.
- Girisha, B. S., D. Kamath, P. Shrinath, and P. S. Harish, 2012. Seborrheic Keratosis; A Rare Cause of Conductive Deafness. Case Report, *Journal of Clinical and Diagnostic Research*, Vol. 6, № 5, pp. 913-914.
- Izikson, L., A. J. Sober, and M. C. Mihm, 2002. Prevalence of Melanoma Clinically Resembling Seborrheic Keratosis: Analysis of 9204 Cases, *Arch Dermatol.*, Vol.138, № 12, pp. 1562-1566.
- Jackson, J. M. et al., 2015. Current Understanding of Seborrheic Keratosis: Prevalence, Etiology, Clinical Presentation, Diagnosis, and Management, *J Drugs Dermatol.*, Vol. 14, № 10, pp. 1119-25.
- Kwon, O. S. et al., 2003. Seborrheic keratosis in the Korean males: causative role of sunlight, *Photodermatology, Photoimmunology and Photomedicine*, Vol. 19, № 2, pp. 73-80.
- Luen, K. K., R. S. Akhama, and W. S. Wan Azman, 2016. Giant seborrheic keratosis of the face – An unusual presentation, *J Dermatol*, Vol. 1, № 1, pp. 25-28.
- Mikhail, G. R., and A. H. Mehregan, 1982. Basal cell carcinoma in seborrheic keratosis, *Journal of the American Academy of Dermatology*, Vol. 6, № 4, Part 1, pp. 500-506.
- Phulari, R. G. S., K. Buddhdev, R. Rathore and S. Patel, 2014. Seborrheic keratosis, *J Oral Maxillofac Pathol*, Vol. 18, № 2, pp. 327-330.
- Rajabi, P., N. Adibi, P. Nematollahi, M. Heidarpour, M. Eftekhari, and A. M. Siadat, 2012. Bowenoid transformation in seborrheic keratosis: A retrospective analysis of 429 patients, *J Res Med Sci*, Vol. 17, № 3, pp. 217-21.

\*\*\*\*\*