



ISSN: 0976-3376

Available Online at <http://www.journalajst.com>

ASIAN JOURNAL OF
SCIENCE AND TECHNOLOGY

Asian Journal of Science and Technology
Vol. 07, Issue, 09, pp.3560-3565, September, 2016

RESEARCH ARTICLE

COMPREHENSIVE ANALYSIS OF AGE RELATED MACULA DETECTION IN DIGITAL RETINAL IMAGES

^{1,*}Shiny Priyadarshini, J. and ²Gladis, D.

¹Madras Christian College

²Presidency College

ARTICLE INFO

Article History:

Received 20th June, 2016
Received in revised form
19th July, 2016
Accepted 27th August, 2016
Published online 30th September, 2016

Key words:

Fundus Image,
Macula,
Segmentation,
Macula Diameter.

ABSTRACT

Retinal disorder is one of the major leading problem for permanent blindness where retinal analysis plays a vital role in diagnosis of retinal diseases. This paper highlights a very simple and straight forward approach for the segmentation of macula from the digital retinal images. The macula is extracted and the diameter is calculated using the mathematical morphological operations and it is also compared with the clinically accepted macula diameter. The results of the present study clearly depict that the extraction of macula for a healthy retina is more accurate than the diseased retina which automatically proves the presence of retinal diseases.

Copyright © 2016 Hidaya S. Saker et al. This is an open access article distributed under the Creative Commons Attribution License, which permits unrestricted use, distribution, and reproduction in any medium, provided the original work is properly cited.

INTRODUCTION

The human eye can be perceived as a digital camera with the retina being the posterior region of eyeball is a thin layer which is mainly responsible for visual recognition. Any damage to retina can cause permanent blindness hence early precautionary steps are necessary (Madhura *et al.*, 2014). The central portion of Retina is called Macula and fovea forms the central part of Macula which is responsible for accurate vision (Charu Sharma *et al.*, 2014; Dhiravidachelvi and Rajamani, 2015). The typical anatomy of retina is shown in Fig.1. Retinal disorders such as Glaucoma, Cataract, Diabetic Retinopathy and AMD are the most commonly found retinal diseases in a human eye. Such diseases require early diagnosis and immediate medical measures, in which Macular Degeneration lacks knowledge even for its existence among common man. The studies on epidemiology of age-related macular degeneration in the Indian Subcontinent (Jyh haur, 2009) shows that the Age related Macular degeneration (AMD) is emerging as a major threat to developing countries like India, Pakistan, Srilanka, Bangladesh, Maldives etc. In India the people with AMD ranges from 1.8% to 4.7% and rest of the countries ranging from 2.1% to 8.7% (Jyh haur, 2009). Visual impairment due to AMD is a significant cause in these countries.

Apart from clinical treatment, awareness and wider knowledge regarding AMD seems mandatory. Recent studies show that about a decade ago the risk factor for AMD prevailed more for aged people than the youngsters. But now the younger generation aged 30- 40 is more prone to the macula disorders due to their sophisticated day today lifestyle. Irreversible blindness is becoming a serious issue in Age related macular degeneration and becomes the third major cause for blindness around worldwide (Jyh haur, 2009). A typical diseased retina commonly called as drusen is depicted in Fig.2.

The extraction of Macula becomes a challenging task to identify the presence of AMD when the retina is diseased. The people with diabetes are at high risk for retinal disorders such as Diabetic Retinopathy (DR). DR is the most commonly found retinal disorders in human beings leading to AMD by gradual progression in disease. The diabetic retinopathy can be progressed into various stages such as Micro-aneurysms, hemorrhages, hard exudates and cotton wool spots (Kanchan Nemade and Bhagat, 2015; Dhariti deka, 2015). Due to the presence of these anomalies the Macula can be disrupted for visual representation by leading to AMD or even disappearance of macula. A typical diabetic Retinopathy with degenerated macula is shown in Fig.3. This paper highlights the segmentation of healthy Macula with fovea and degenerated Macula.

*Corresponding author: Shiny Priyadarshini, J.,
Madras Christian College.

Existing Work

Niemeijer *et al.*, (2008) presented localization of optic disc and fovea in retinal images.

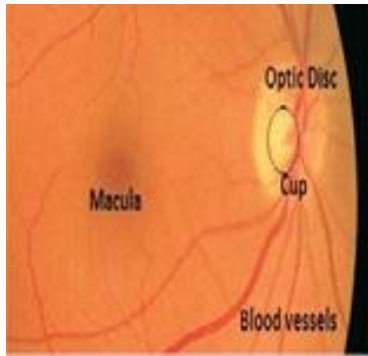


Fig.1. Anatomy of retina

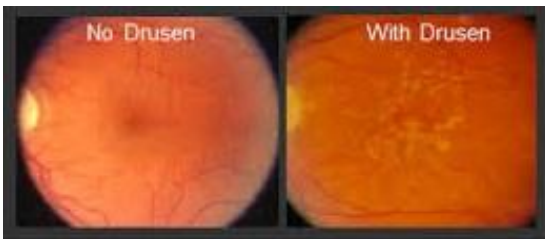


Fig.2. Normal Retina- Diseased Retina (Drusen)

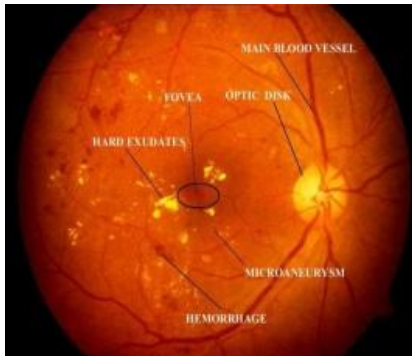


Fig. 3. Diabetic Retinopathy

Ziyang *et al.*, (2010) presented the automatic detection of AMD using Grading overlay techniques. Soumitra Samanta *et al.*, (2011) presented a simple and fast algorithm using Mathematical morphology in retinal images. Priya *et al.* (2013) presented the diagnosis of DR in retinal images using Wavelett transform and Fuzzy C-means segmentation. Nyni *et al.* (2014) presented Macula detection using morphological operations in retina. Charu sharma *et al.* (2014) presented segmentation using Fuzzy C-means and Neural Networks and diagnosed the presence of DR. Dhiravidachelvi *et al.* (2015) presented the diagnosis of DR in fundus images. Raju Maher *et al.* (2015) automatic detection of DR using Fuzzy C- means in fundus images. Jadhav *et al.* (2015) presented calculation of blood vessel area and identified the presence of DR in fundus images using morphological operations. Kanchan Nemade *et al.* (2015) presented the detection of retinal abnormalities and graded the severity of disease. Dhariti deka., *et al* (2015) presented the detection of Macula and fovea using Haar wavelet transformation. Jyh haur., *et al* presented the history of AMD in India and its surrounding regions.

Proposed Methodology

This paper focuses on the segmentation of macula from a retinal image and to identify the presence of AMD. Although existing work shows many techniques and methodologies (Soumitra Samanta, 2011), (Priya and Aruna, 2013; Raju Maher *et al.*, 2015; Dhariti deka, 2015) this articles focuses on the segmentation of AMD with an unpretentious approach. The macula is segmented from both healthy and unhealthy human retina so that the presence of AMD can be analyzed.

The retinal image is enhanced in the pre-processing stage by applying histogram equalization and binarization techniques. Macula is then segmented using the morphological operations. An analysis has been made in the post processing stage with the macula diameter calculated from retinal images. The outline of feature extraction of macula is shown in Fig.4(a) and its detailed methodology in Fig 4(b).

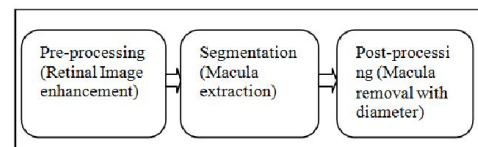


Fig.4(a). Stages in Macula feature extraction

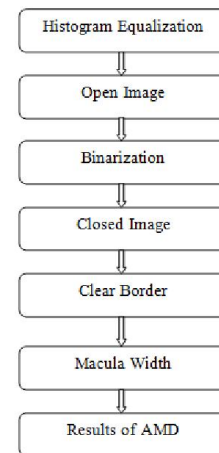


Fig. 4(b). Proposed Methodology

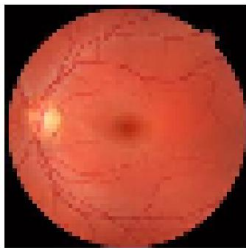
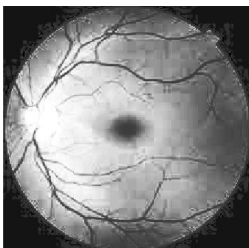



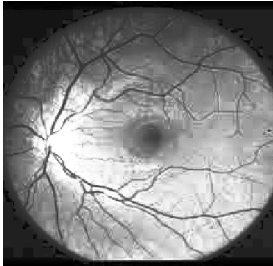



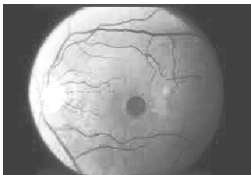



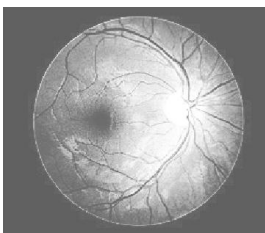






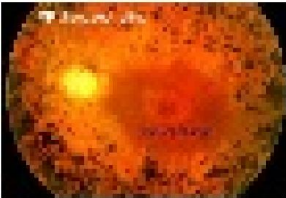
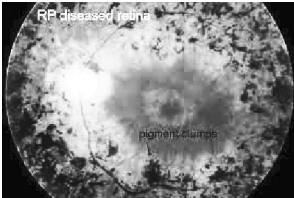



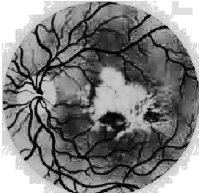


Retina Pre-Processing

Histogram equalization

The retinal image is enhanced using histogram equalization. It is a process of transformation where the intensities of the image are adjusted and the resultant image is a high contrast image. The image is enhanced to visualize its minute details accurately (Soumitra Samanta, 2011). The Histogram equalized image is shown in Fig 5.

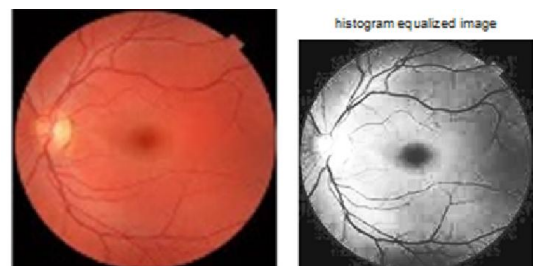

Fig.5. Original image with its histogram equalized

<i>Normal Retina</i>			
<i>Original image</i>	<i>Histogram Equalized image</i>	<i>Open image</i>	<i>Close image</i>
Original Image 	histogram equalized image 	Opened Image 	Closed Image 
Original Image 	histogram equalized image 	Opened Image 	Closed Image 
Original Image 	histogram equalized image 	Opened Image 	Closed Image 
Original Image 	histogram equalized image 	Opened Image 	Closed Image 
<i>Macular Degenerated Retina</i>			
Original Image 	histogram equalized image 	Opened Image 	Closed Image 
Original Image 	histogram equalized image 	Opened Image 	Closed Image 
Original Image 	histogram equalized image 	Opened Image 	Closed Image 

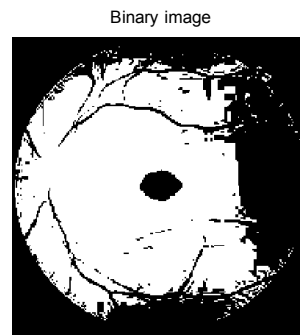


Fig. 6. Original image with its binarized image




Fig. 6. (a) Open image 6(b) Closed image 6(c) Clearing border

Segmentation

Binarization

Binarization is done after the histogram equalization of an image (SujithKumar and Vipula Singh, 2012; Damon and Wong, 2012). Binary image has only two possible values, zero's and one's which are normally displayed as black and white. The retinal image is binarized where the 8 bit gray image is transformed into a 1 bit image. The image is transformed into black and white colour, where the darker regions become black and the rest of the region with white colour. The binarized image is shown in Fig 6.

Morphological operations

The fundus image is given as input to perform the morphological operations open and close which are similar to erosion followed by dilation (Ziyang Liang, 2010)(Damon and Wong, 2012). The basic idea is to remove the bright pixels from the edges of the image for opening of an image followed by enlarging the boundaries of foreground regions of an image so that the holes in the image are filled up and gets smoothed after closing. The structuring element also plays an important role in morphological operators as it decides the exact operation. The required shape here is a circular structure which happens be the Macula therefore the structuring element used here is "disk" shape. Fig 6 (a),(b),(c).depicts the transformation of images after applying the morphological operations open and close with its border cleared image.

Retina Post-Processing

Macula extraction and Radius calculation

The central macula region is extracted after applying the morphological operations by clearing its border and is taken for the calculation of its diameter and radius.

This is done by calculating the area of entire macula from which the major axis length and the minor axis length is calculated. Then the diameter and radius of the macula is calculated by using the formula,

$$\text{Diameter} = (\text{major axis length} + \text{minor axis length})/2$$

$$\text{Radius} = \text{Diameter}/2$$








The results are matched with clinical dimensions of macula and an analysis has been done whether it's related to normal healthy human retina or not. The clinical macula dimension is 5.5 mm which is shown in Fig 7.

Simulation Results

In pre-processing stage the retinal image is enhanced using Histogram equalization and the Macula is segmented using the Mathematical morphological operations. Table 1 and 2 represents a sample of seven retinal images taken from the DRIVE database, the first five representing the normal healthy human retina and last three macula degenerated retina. About fifty samples were tested and the results were satisfactory where few examples are shown in Table 1 and 2.

Table 1 shows the result of morphological operations done for seven retinal images after applying histogram equalization. Table 2 depicts the result of macula segmentation for the same set of samples with its diameter and radius being calculated. The clinical value of Macula diameter shows 5.5 mm which is equal to 21 pixels approximately. The results show that the radius values ranges between 19-29 pixels for normal macula which is equal to 5-7 mm diameter whereas showing absurd values when macula cannot be segmented which is shown clearly in Table 3.

Table 2.

Normal Retina			
Segmented Macular image	Diameter (pixels)	Radius (Pixels)	Results
cleared border image 	24.9248	12.4624	Macula located
cleared border image 	29.5786	14.7893	Macula located
cleared border image 	19.9870	9.9935	Macula located
cleared border image 	21.1350	10.5675	Macula located
Macular Degenerated Retina			
cleared border image 	45.4388	22.7194	Macula not located (radius cal for two spots)
cleared border image 	121.034	60.5172	Macula not located (radius cal for three spots)
cleared border image 	197.833	98.9167	Macula not located (radius cal for whole image)

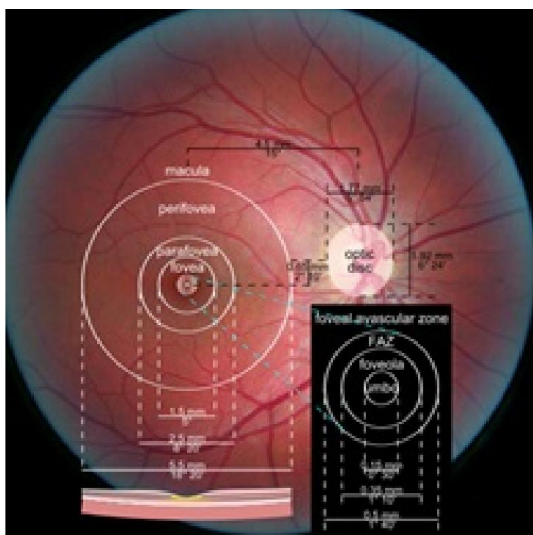


Fig.7. Macula dimensions

Table 3.

Diameter for normal Macula in retina (pixel). Actual size= 21 px	Diameter for normal Macula in retina (mm). Actual size= 5.5 mm
24.9248	6.594686667
29.5786	7.826004583
19.9870	5.288227083
21.1350	5.59196875

Conclusion

The results clearly show that the Macula can be segmented using morphological operations for normal human retina when compared to macular degenerated retina. The radius of diseased retina shows absurd result when compared to normal retina by showing the presence of macular degeneration with anomalies. So it's concluded that the Macula can be segmented only from normal retina which can be easily differentiated from abnormal retina and also helps to identify the presence of retinal diseases.

REFERENCES

Charu sharma, Geeta Kaushik, 2014. "Automatic Diagnosis of Diabetic Retinopathy Using Fundus Images, Vol 4, ISSN: 2277 128X, May.

Damon, W.K. Wong *et al.* 2012. "Automatic Detection of the Macula in Retinal Fundus Images using Seeded Mode Tracking Approach" IEEE.

Dhariti deka *et al.* 2015. "Detection of Macula and Fovea for disease Analysis in color fundus images" IEEE.

Dhiravidachelvi, E., Rajamani, V. 2015. "A Novel Approach for Diagnosing Diabetic Retinopathy in Fundus Images" Journal of Computer Science.

Jadhav, A.S, 2015. Pushpa B.Patil, "Classification of Diabetes Retina Images using Blood Vessel Area" Vol 4 (IJCI) April.

Jyh haur 2009. "Epidemiology of age related macula degeneration in the indian subcontinent" 2009.

Kanchan Nemade, Bhagat K.S. 2015. "Microaneurysms Detection from Retinal Image and Diabetic Retinopathy Grading" Vol 4, ISSN:2278-6856, Aug 2015.

Madhura J P., Kakatkar M N., " Review of Methods for Diabetic Retinopathy Detection and Severity Classification" IJRET, Vol 3, ISSN: 2321 7308, March 2014.

Niemeijer, M., Abramoff, M.D. and van Ginneken, B. 2008. "Automated localization of the optic disc and the fovea", in 30th Annual International IEEE Engineering in medicine and biology society Conference, Canada, pp. 3538-3541.

Nyni, K. A. and Drisya, M. K. 2014. Neethu Rose Thomas., "Detection of Macula in Retinal Images using Morphology", Vol 4, ISSN: 2277 128X, Jan 2014.

Priya, R. and Aruna, P. 2013. "Diagnosis of Diabetic Retinopathy Using Machine Learning Techniques" Vol 3, ISSN: 2229-6956, July 2013.

Raju Maher, S. Kayte, Mukta, 2015. "Review of Automated Detection for Diabetes Retinopathy Using Fundus Images, Vol 5, ISSN: 2277 128x, March 2015.

Soumitra Samanta, S. Kumar Saha and Bhabatosh Chanda A. 2011. Simple and Fast Algorithm to Detect the Fovea Region in Fundus Retinal Image", Second International Conference on Emerging Applications of Information Technology, IEEE pp. 206-209.

SujithKumar, S.B. Vipula Singh. 2012. "Automatic detection of Diabetic Retinopathy in Non-dilated RGB Retinal Fundus Images", Vol 47, June.

Ziyang Liang *et al.* 2010. "Towards automatic detection of age-related macular degeneration n retinal fundus images" IEEE sep 2010
