

CASE REPORT

SPONTANEOUS CHRONIC SUBDURAL HEMATOMA IN A 12 YEARS OLD BOY A RARE CASE REPORT

^{1,*}Dr. Dinesh Sodhi, ²Dr. Neelima Arora Sodhi and ³Dr. Ritu Gaur

¹Department of Neuro Surgery, S.P. Medical College, Bikaner, India

²Department of Pathology, S.P. Medical College, Bikaner, India

³Gaur, Resident, General Surgery, S.P. Medical college, Bikaner, India

ARTICLE INFO

Article History:

Received 11th August, 2015

Received in revised form

02nd September, 2015

Accepted 21st October, 2015

Published online 30th November, 2015

ABSTRACT

Spontaneous chronic subdural hematoma in childhood or adolescence is very unusual. Most of the subdural hematomas are due to head injury. Here we are presenting a case of a 12 year old boy whose computed tomography and magnetic resonance imaging depicted a chronic subdural hematoma in the left frontotemporoparietal region with mass effect.

Key words:

Spontaneous,
Subdural Hematoma (SDH),
Computed Tomography (CT),
Magnetic Resonance Imaging (MRI).

Copyright © 2015 Dr. Dinesh Sodhi et al. This is an open access article distributed under the Creative Commons Attribution License, which permits unrestricted use, distribution, and reproduction in any medium, provided the original work is properly cited.

INTRODUCTION

SDH is collection of blood in the potential space between dura and arachnoid mater of the meninges. Etiology of SDH is mainly traumatic. Spontaneous chronic SDH is rare in childhood. The literature is limited to sporadic case reports. Incidence rate of non traumatic SDH is 3-5% (Avis SP, 1993, Sung SK, 2012). They predominantly affect adults in their 5th to 7th decades (Marconi F, 1991) and are rare in children.

Case report

A 12 year old boy presented to the department of paediatrics with history of severe headache from last 8 days and convulsions with altered sensorium from 1 day. He had no history of trauma. There was no history of anticoagulant therapy or coagulopathy. On neurological examination patient had right sided weakness. Patient's haematological and biochemical parameters were normal. The coagulation profile was within normal limits. CT and MRI identified left sided mixed density and high signal intensity indicative of chronic SDH (Fig 1,2). There was midline shift towards right side with evidence of descending transtentorial herniation and mild brainstem compression.

The patient was taken for burr hole and evacuation of chronic SDH. The evacuated hematoma had dark appearance typical of chronic SDH. The post operative period was uneventful. During follow up period MRI brain and CT cerebral angiography was done to exclude vascular risk factors and no abnormality was found.

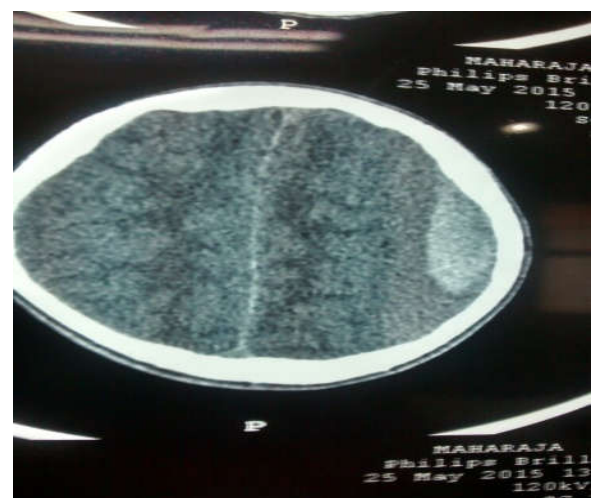

Fig 1.

*Corresponding author: Dr. Dinesh Sodhi,
Department of Neuro Surgery, S.P. Medical College, Bikaner, India.

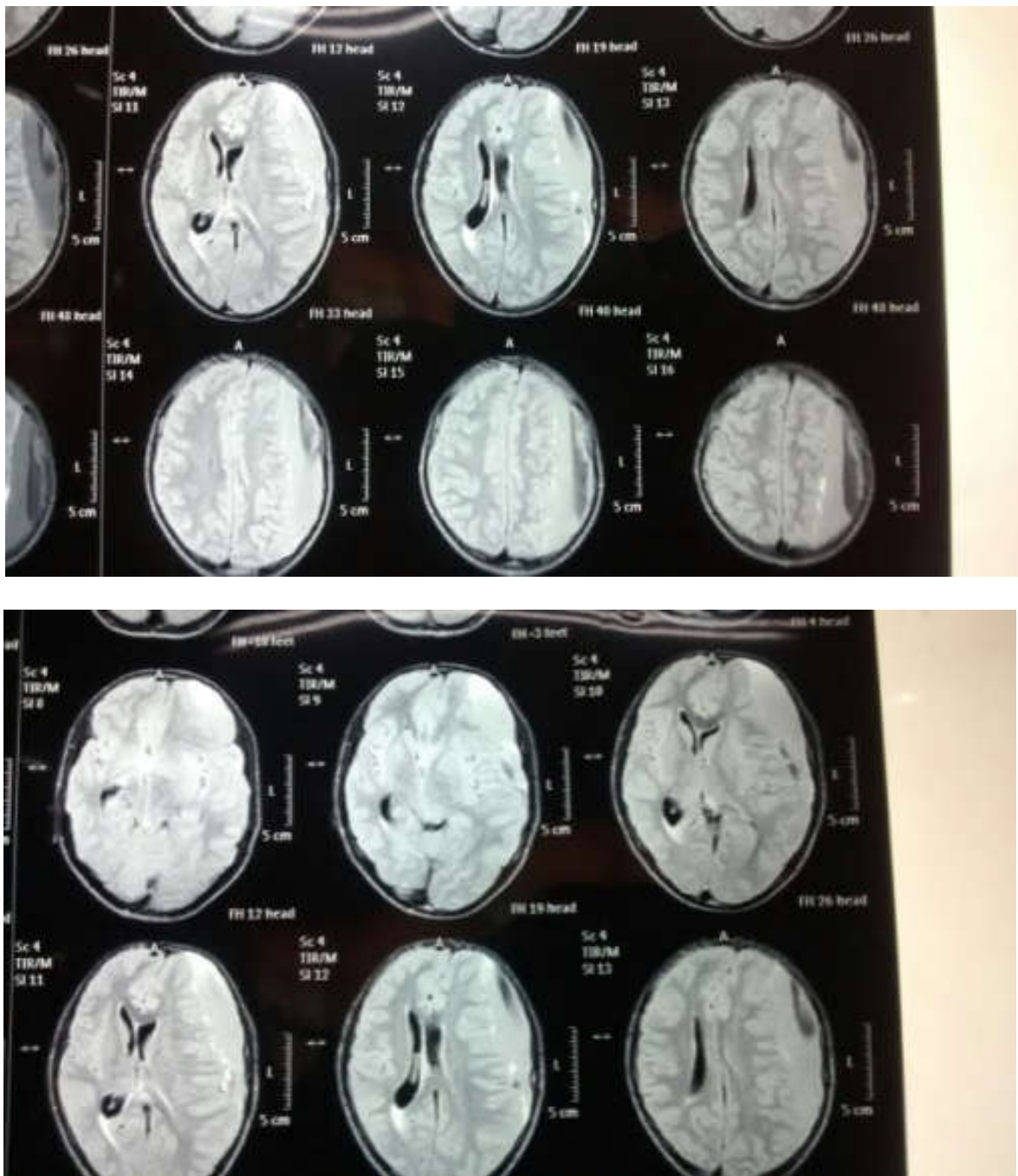


Fig. 2.

DISCUSSION

Non traumatic SDH is a rare pathological entity accounting for less than 5% of SDH. Hematological disorder, arteriovenous malformation, cerebral aneurysm or anticoagulant therapy may predispose to the development of spontaneous SDH. None of these predisposing factors were present in our case. Spontaneous SDH appearing in the absence of predisposing factors is very rare. CT scan allows accurate and prompt diagnosis of SDH. Cerebral angiography is needed to exclude vascular abnormalities and coagulation profile is required to exclude coagulation abnormalities. Symptomatic SDH requires surgical treatment, specially when there are neurological symptoms, seizures or chronic headaches. In our case, surgical evacuation of the chronic SDH was done with a good outcome.

REFERENCES

- Avis, S.P. 1993. Nontraumatic acute subdural hematoma. A case report and review of the literature. *Am J Forensic Med Pathol* 14:130–134. [PubMed]
- Sung, S.K., Kim, S.H., Son, D.W. and Lee, S.W. 2012. Acute spontaneous subdural hematoma of arterial origin. *J Korean Neurosurg Soc.*, 51:91–93. [PMC free article] [PubMed]
- Marconi, F., Fiori, L., Parenti, G. and Ravelli, V. 1991. Acute spontaneous subdural haematoma. Description of four clinical cases. *J. Neurosurg Sci.*, 35:97–102. [PubMed]
