Available Online at http://www.journalajst.com

ASIAN JOURNAL OF SCIENCE AND TECHNOLOGY

ISSN: 0976-3376

Asian Journal of Science and Technology
Vol. 17, Issue, 10, pp. 14640-14649, October, 2026

RESEARCH ARTICLE

LIGHT AND SCANNING ELECTRON MICROSCOPIC STUDIES OF ECTOPARASITES IN *LABEO ROHITA* IN LUCKNOW REGION, INDIA

Kamal Jaiswal[1], Suman Mishra[2], Deepshikha[3]* and Swati[4]

[1,2]Professor, Department of Zoology, Babasaheb Bhimrao Ambedkar University, Lucknow, Uttar Pradesh, India; [3]Postgraduate Student, Department of Zoology, Babasaheb Bhimrao Ambedkar University, Lucknow, Uttar Pradesh, India; [4]Resource Person, Department of Zoology, Babasaheb Bhimrao Ambedkar University, Lucknow, Uttar Pradesh, India

ARTICLE INFO

Article History:
Received 18th July, 2026
Received in revised form
20th August, 2026
Accepted 14th September, 2026
Published online 30th October, 2026

Key words:
Ectoparasite, *Labeo rohita, Myxobolus, Trichodina, Thelohanellus, Lernaea,* Cyprinid, Myxosporean, Ciliophoran, Scanning electron microscopy, Light microscopy.

***Corresponding author:**
Deepshikha

ABSTRACT

The present study was conducted to isolate and identify ectoparasites of the cultured major carp *Labeo rohita*, collected from different pond regions of Lucknow District, Uttar Pradesh, India. Out of 38 fishes examined, 32 (84.21%) were infected with ectoparasites belonging to four groups: *Myxobolus, Trichodina, Thelohannellus, and Lernaea*. Among the examined fishes, 15.78% were infected with *Myxobolus*, 52.63% with *Thelohanellus*, 42.10% with *Trichodina,* and 3.21% with *Lernaea. Myxobolus, Trichodina, and Thelohanellus* were recorded from the gills. *Myxobolus* and *Thellohanellus* were present as whitish cysts on the gills, whereas *Trichodina* was collected from the black-colored body surface. *Lernaea* was collected from the caudal fin of the fish. The highest prevalence was observed for *Thelohanellus*, while the lowest was recorded for *Lernaea*. Cyprinid fish infected with the microparasites, including myxosporeans and ciliophorans, did not show severe pathogenic signs; however, increased mucus production on the gill surface and creamish-white plasmodia were observed. Fish infected with the macro parasite copepod showed lesions on the caudal fin at the site of attachment. The clinical signs included increased mucus production, floating at the water surface, and mortality. The morphological characteristics of the parasites were studied using light microscopy and scanning electron microscopy. This study represents the report of the multiple ectoparasitic infestations in *Labeo rohita* in the Lucknow region.

Citation: ***Kamal Jaiswal, Suman Mishra, Deepshikha and Swati.*** **2023.** "Light and scanning electron microscopic studies of ectoparasites in *labeo rohita* in lucknow region, India*". Asian Journal of Science and Technology*, 17, (10), 14640-14649.

Copyright©2026, Kamal Jaiswal et al. *This is an open access article distributed under the Creative Commons Attribution License, which permits unrestricted use, distribution, and reproduction in any medium, provided the original work is properly cited.*

INTRODUCTION

Labeo rohita being an inland species is commonly cultured in India. It is considered as one of the most important fish because of its nutrition content, rich taste, high market value, high fecundity rate, high food conversion ratio, high economic return, availability of fry and fingerlings for culturing etc. Along with the advancement of technologies like induced carp breeding and polyculture practices of Indian major carps (*Catla catla, Labeo rohita* and *Cirrhinus mrigala*) due to compatibility of rohu with other major carps have also brought an upward positive shift in freshwater aquaculture production sector (Jayasankar, 2018). It is reported that pisciculture is directly hampered nowadays by parasitic infestation. Also, many studies have reported that *Labeo rohita* is more susceptible to diseases and parasitic infestation as compared to the exotic carps that are regularly being cultured (Lilley *et al.,* 1992). Fish parasites are reported to have direct effect on fish health (Hoffman, 1967). Generally, it is reported that fish parasites survive in host's intestine or in the host's tissue. They tend to multiply their numbers rapidly in favorable conditions (Dogiel, 1956), leading to economic loss as they affect fish health which further increases their mortality rate (Tripathi, 1959). The temperature of water makes environment conducive to diseases and parasites growth. The fish parasites generally feed on intestine digested content, muscles, tissues, or even on the host's blood. It not only interferes with the nutrition value but also the metabolism. It disrupts secretory functions of alimentary canal and normal operation of nervous system (Markov *et al.*, 1961). Parasites cause mechanical damage like fusion of gill lamellae, replacement of tissue, physiological damage like cell proliferation, detrimental behavioral changes, altered reproductive and growth cycle inside the host body (Iwanowicz, 2011). Recently protozoan ectoparasites infections in *Labeo rohita* have drawn the attention of many parasitologists. Ectoparasites live on the surface of body of large animals and they depend on them for food, shelter and other basic needs to survive. It has been found that ectoparasites of *Labeo rohita* directly affect the host body and sometimes it transmits pathogens that act as vectors of diseases. Fishes harbor variety of ectoparasites but the damage to host body depends on the number and type of parasites (Bauer, 1941).

Large number of parasitic presences could lead to pathological changes (Heckman, 1996; Hoffman, 1998). Heavy parasitosis could cause mass mortalities, secondary infections like bacterial or fungal in the fish population (Lester & Haywood, 2006). Protozoan ectoparasites are the most commonly encountered parasite among fishes (Klinger & Floyd, 2002). The main groups include the ciliates, flagellates, microsporidians, ciliophora, and myxozoans. These parasites can multiply to large numbers inside the body of host fish if fishes are kept under crowded environment, which may result into weight loss, debilitation of the host and ultimately mortality (Klinger & Floyd, 2002). Out of this myxozoan protozoan, parasite like *Thelohanells* and *Myxobolus* are economically important parasites to be studied as they infect the fish population which are harvested for food. These parasites form spores and are found in both marine and freshwater fishes (Lom & Dyková, 1992, Kent *et al.,* 2005; Feist & Longshaw, 2006). They cause diseases like myxoboliosis, whirling disease, myxosporean sleeping disease, gill myxoboliosis, cysts in gill or hepatopancreas, thelohanellosis which may affect the normal functioning of the organs ultimately leading to economic losses (Gupta & Kaur, 2017). Pathogenic myxosporean parasite has been reported to cause hemorrhagic gill disease in *Labeo rohita* (Hamilton, 1822; Kaur *et al.*, 2014). Another diverse ciliophoran protozoan parasite, *Trichodina* which is a ciliated parasite with adhesive disc like complex structures (Basson & Van, 2006). It is one of the main causes of diseases in cultured fishes leading to economic losses worldwide. These are the most common parasitic ciliates, widely dispersed in many zoogeographical areas (Lom & Dyakova, 1992). Species of this genus causes a serious disease called trichodiniasis, which is a major concern for aquaculture throughout the world. It feeds on the detritus and debris found on the surface of the fish body by using its tooth-like structures called as denticles. When these parasites are present in large numbers, the scraping action and movement of these organisms irritate the skin and gill surfaces of the fish. Crustacean parasitic groups that are found in cultivable finfish are; Branchiura, Copepoda and Isopoda. Copepods are important to be studied as they are destructive and common pathogenic small crustacean ectoparasites of fishes found in Asian countries. *Lernaea* one of them is extremely common among the cyprinid fishes. It is also known as 'anchor worm'. It is small crustacean, copepod ectoparasites that can cause disease in many types of freshwater fishes, generally in cultured and wild-caught species. In cases of severe infection, the mortality rate also increases. It has been reported to infect gills, fins, skin, and oral cavity of fishes resulting into skin abrasions, pale gills, severe hemorrhaging, destruction of oral mucosa, and ulcerative lesions at the site of attachment to host body extending to muscles leading to irritation and death ultimately (Hossain *et al*., 2013). It is reported to cause serious disease like lernaeosis. So, for this reason the understanding on morphology and diverse effects of fish ectoparasites on its hosts is needed. Also to prevent the problems associated with parasites it is significant to know the mechanism of parasitic infestation. With increasing attention towards parasitism and disease being a threat to environment of fishes there is a need to identify pathogens, parasites and associated risks for hosts (Daszak *et al.,* 2000; Smith *et al.,* 2006). Also, the successful pisciculture and implementation of associated programs with fishes depends on more quality parasitological research in the field (Bhuiyan *et al.,* 2007). The investigations and studies directed towards morphology of ectoparasites and their identification will play a significant role in designing strategic control towards these parasites. Ectoparasites' distribution in some parts of our country is still not known. To achieve effective control measures of ectoparasites of fish, their geographical location, morphology, stage of fish life cycle that are normally being infested and different stages of these parasites' life cycle should also be known. Duly considering the limited information on morphology of ectoparasitic infestation of fishes in the study area, in order to report new findings and due to the importance of fishes in the national economy this study aimed to explore morphological features of the ectoparasites of *Labeo rohita* with the help of light and scanning electron microscopic method. Types of ectoparasites found in host fishes under study are *Myxobolus, Trichodina, Thelohanellus* and *Lernaea,* in Lucknow, India and have been described morphologically and morphometrically.

METHODOLOGY

Total number of 38 fishes were collected randomly from Aurangabad Jagir and Kalli Poorab, Lucknow, Uttar Pradesh located at 26°76′72.97′′ N and 80°91′26.45′′ E and 26°71′07′′ N and 80°95′11′′E respectively during February to May months. To know the real scenario of the fish culture ponds and also to understand about fish parasites, an interaction with local fishermen was done. Fishes were collected through net by the fisherman and were brought to parasitology laboratory of the institute by researchers after procurement for examination of the ectoparasites. The sex, length, body weight of fishes, type of farming practice and farm sites of the fishes were initially noted. Firstly, to examine ectoparasites, the host body parts including its fins, scales, skin, fin base, eyes etc., were observed under a magnifying glass for any kind of lesions or cysts. Then visceral organs like gills and gut were examined thoroughly for similar kind of parasitic infections after dissection with laboratory protocols.

For light microscopy: *Wet mounting*- Ectoparasites (*Thelohanellus, Myxobolus* and *Trichodinia*) were isolated from the body surface, fins and gills of host fish by scrapping down body slime with help of a scalpel, it was then mixed with a drop of 0.90% of physiological saline, then a smear was spread on glass slide to be observed under the light microscope. Plasmodia were removed from the site of gills and examined under the EVOS-digital microscope at 800X magnification. *Lerneae* parasites were removed with help of forceps from the site of attachment and were placed on a clean glass slide to be observed under EVOS- digital microscope at 20X. *Giemsa staining*- A thin smear of specimen was spread on a clean glass slide and was left to air dry. The smear was dipped (2-3 dips) into pure methanol for fixation and was left to air dry for 30 seconds. Then the slide was flooded with 5% Giemsa stain solution for 30, 60, and 90 minutes for getting better results. After this the slide was flushed with distilled water, air dried and observed.

For Scanning electron microscopy: Mucus containing parasites from gills and body surface, and plasmodia from of gills were collected in an Eppendorf tube through scrapping and centrifuged 3 times at the speed of 14000 rpm for 5 minutes each. The supernatant was discarded and pallet was mixed with 2.5% Gluteraldehyde and kept for 5-6 hours at 4° C. Samples were washed in 0.1 M Phosphate Buffer, for 3 changes each for 15 minutes at 4°C followed by centrifugation after each change, which was done to remove the unreacted fixative.

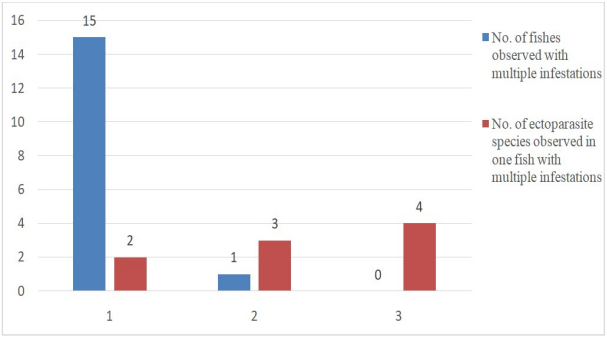

Graph 1. Showing multiple infestations (interspecific association between ectoparasites) in an individual fish

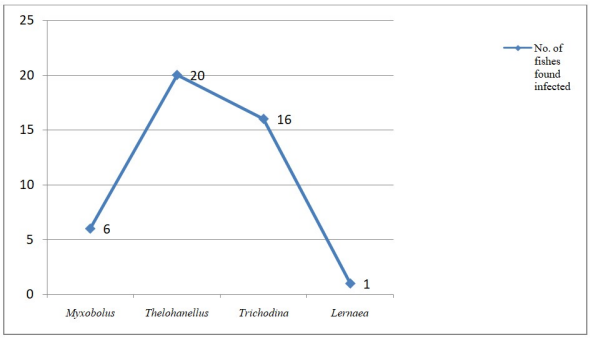

Graph 2. Showing number of fishes found infested with a particular type of ectoparasite out of total number of fishes observed

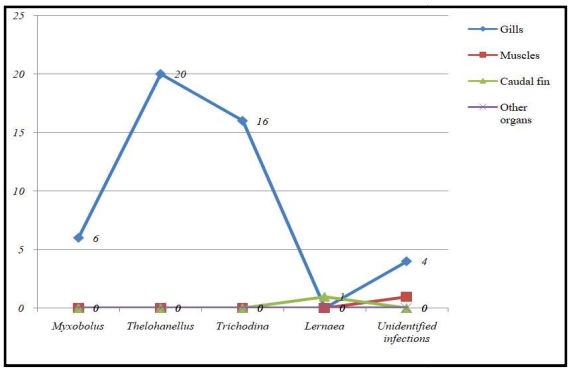

Graph 3. Showing number of fishes infested with a single type of ectoparasite collected from different sites

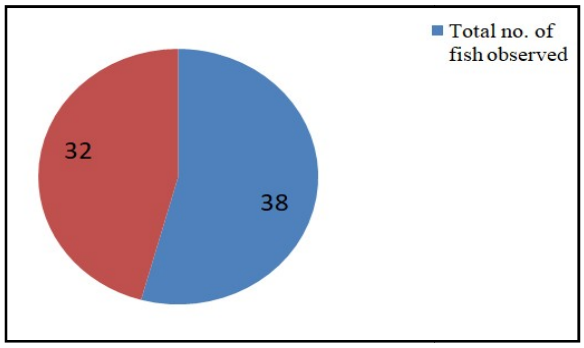

Graph 4. Showing number of fishes observed and total number of fishes found infested with ectoparasites after dissection

Samples were then dehydrated using increasing concentration of Acetone 30%, 50%, 70%, 90%, 95% and 100%, 30 minutes each at 4°C. After that samples were mounted on the Alluminium Stubs with Carbon tape and dried using Critical Point Dryer. After drying, the samples were coated with sputter and observed under JEOL JSM 6490 LV Scanning Electron Microscope of University Sophisticated Instrumentation Centre, Babasaheb Bhimrao Ambedkar University, Lucknow and images were captured.

RESULTS

In the present study 32 out of 38 (84.21%) fishes (*Labeo rohita*) were found infected with ectoparasites belonging to four groups i.e. cnidarian, myxosporeans, ciliophorans and copepods namely *Myxobolus, Trichodina, Thelohanellus* and *Lernaea.* Infection was reported in the small sized fishes within the age group between 3-5 months, average weight 438 g and average length of body 27cm. 15 out of 38 (39.47%) fishes showed multiple infestations which also indicates interspecific interaction between the ectoparasites as reported in the present study. Out of 38 fishes15.78% (6/38) fishes were infected with *Myxobolus* and the parasites were present within the white coloured cysts on the gill filaments showing excessive mucous secretion on the gill surface.

The parasites were pyriform symmetrical in their shapes with tapering anterior end and bulb like posterior end and spore valves were present on the anterior side and two equal sized polar capsules were present in the middle occupying 2/3 of the spore with a vacuole present posteriorly. 42.1% (16/38) fishes were infected with *Trichodina* and parasites were collected from the black coloured body surface having massive loss of scales. The body of the parasite was radially symmetrical, disc shaped, with a ring of interlocking cytoskeletal denticles on the adhesive discs and ciliary spiral. 52.63% (20/32) fishes were infected with *Thelohanellus* and the parasites were present as whitish cyst on the gills.

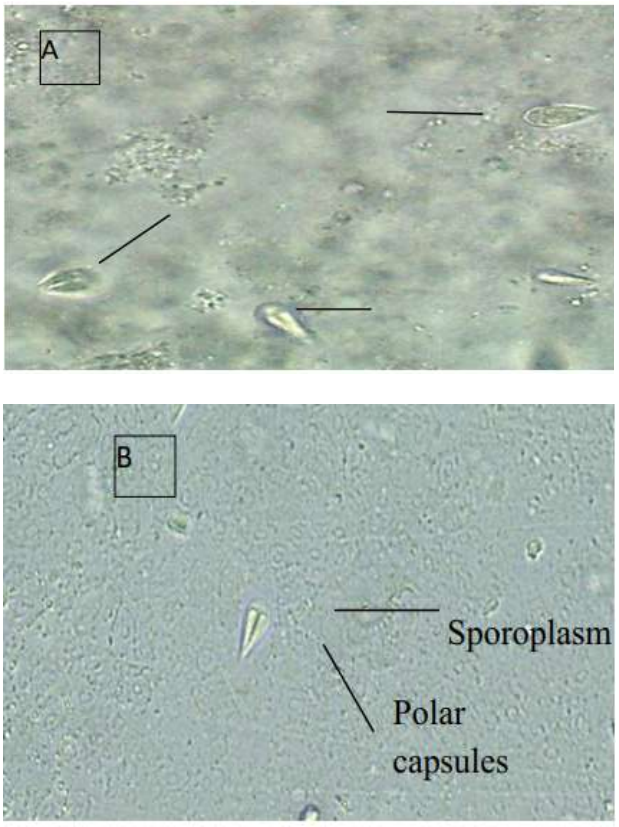

Figure 1.A-B *Myxobolus sp*. collected from the gills of *Labeo rohita*

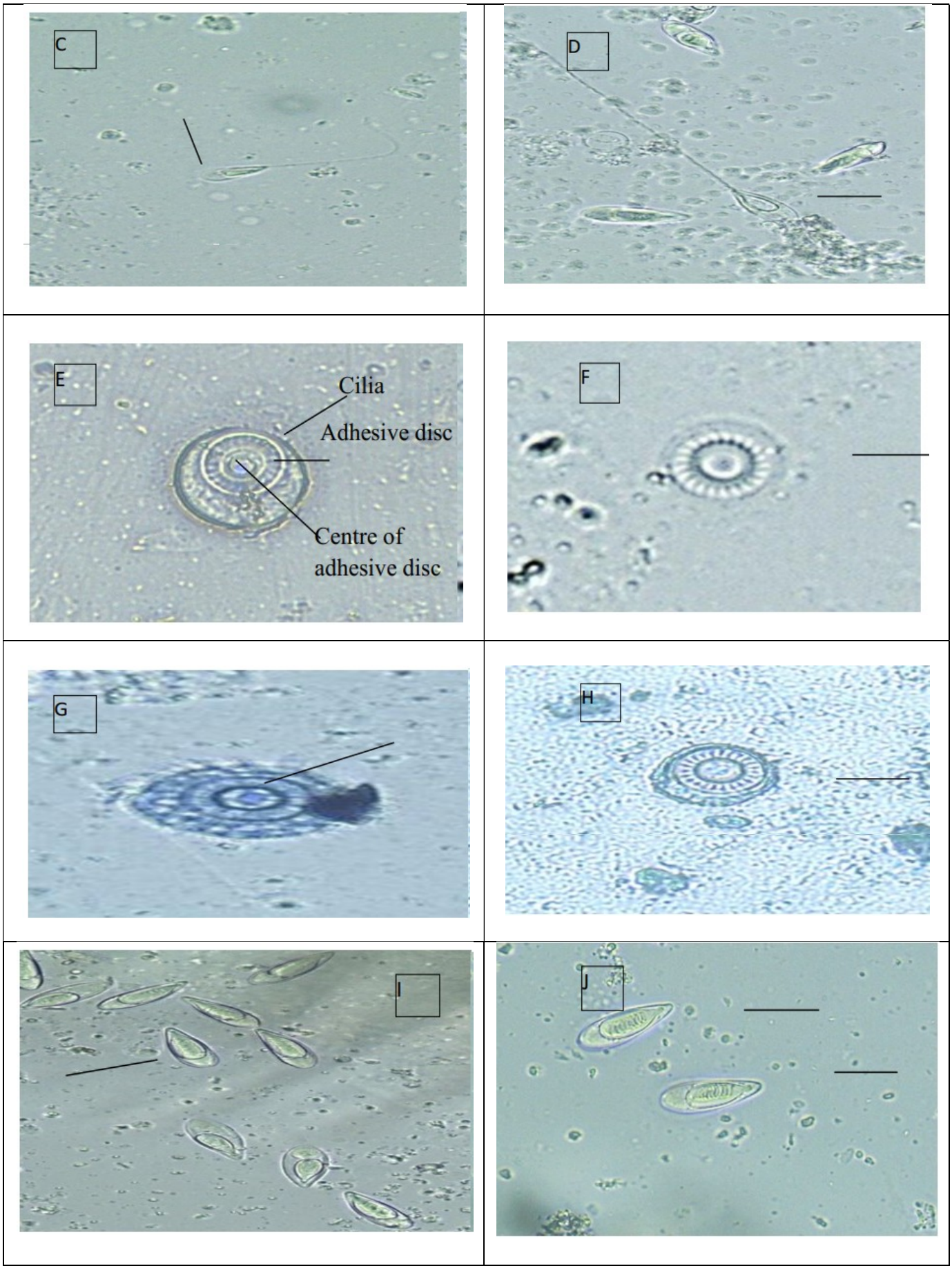

Figure 2. C-D *Myxobolus sp.* collected from the gills of *Labeo rohita*, E-F: *Trichodina sp.* collected from the gills of *Labeo rohita*, G-H: *Trichodina sp.* giemsa stained, I-J: Colony of *Thelohanellus sp.* collected from the gills of *Labeo rohita*

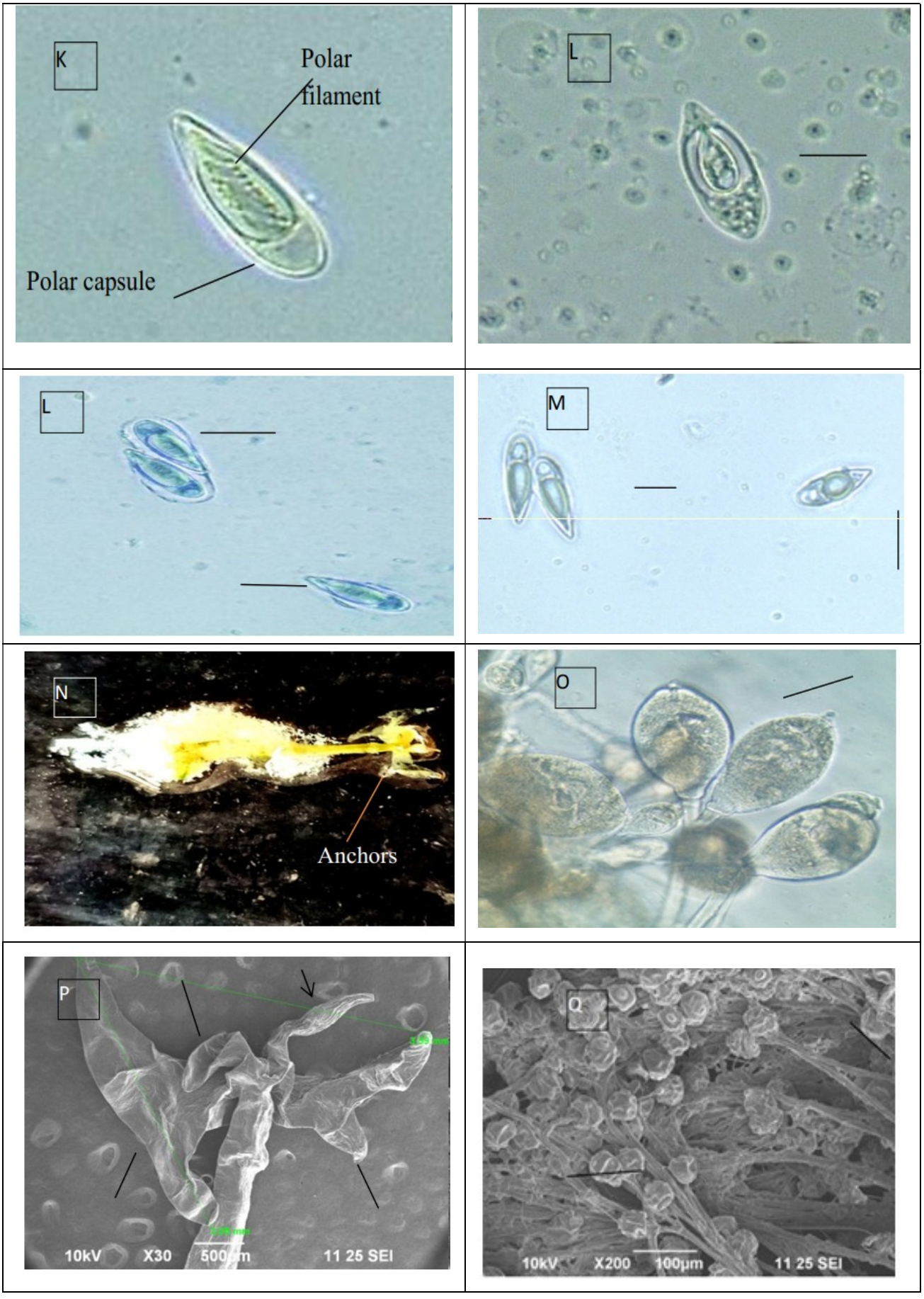

Figure 3: K-L: *Thelohanellus sp.* individuals collected from gills of *Labeo rohita*, L-M: *Thelohanellus sp.* Giemsa stained, N: *Lernaea* as visible from naked eye collected from the caudal fin of *Labeo rohita*, O: Nauplius larval stage of *Lernaea,* P: Showing distance between two anchors of *Lernaea* under scanning electron microscope, Q: Posterior part of female *Lernaea* showing nauplius stages attached to the embryo sac observed under scanning electron microscope

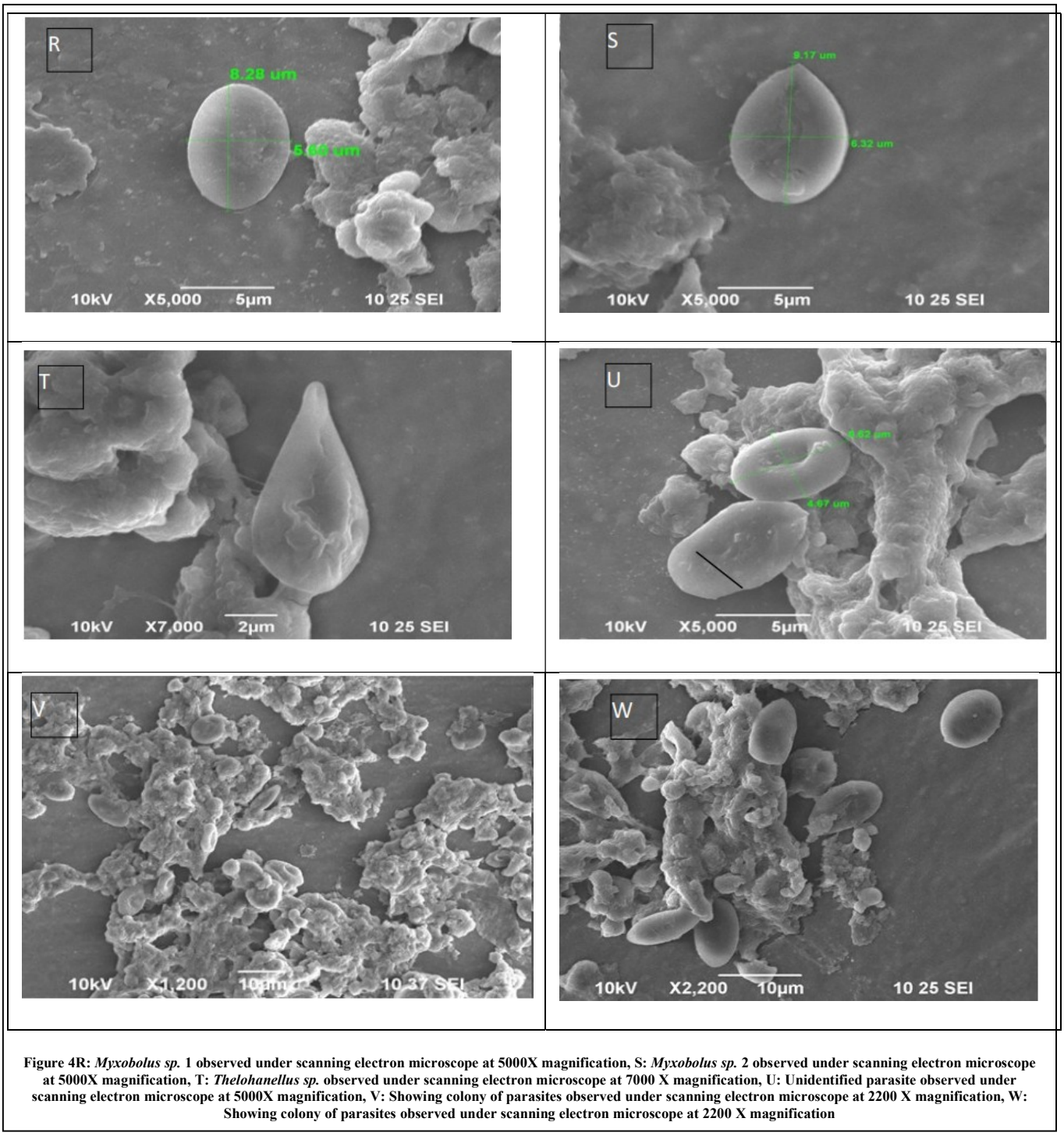

Figure 4R: ***Myxobolus sp.*** **1 observed under scanning electron microscope at 5000X magnification, S:** ***Myxobolus sp.*** **2 observed under scanning electron microscope at 5000X magnification, T:** ***Thelohanellus sp.*** **observed under scanning electron microscope at 7000 X magnification, U: Unidentified parasite observed under scanning electron microscope at 5000X magnification, V: Showing colony of parasites observed under scanning electron microscope at 2200 X magnification, W: Showing colony of parasites observed under scanning electron microscope at 2200 X magnification**

After rupturing the cyst, shape of the parasite was tear shaped, ellipsoidal and symmetrical with spore valves and single polar capsule, containing prominent turns of polar filament. 3.21% (1/32) fishes were infected with *Lernaea*. It was found firmly attached from the caudal fin of the fish causes ulcerated lesions on the attachment site. Parasite showed anchors on the anterior side of the body, varying slightly in length, anterior ventral pair was simple, dorsal pair was T-shaped, two egg sacs were located on the posterior side of body of parasite. Size of the parasite was observed 0.9-1cm. Neck was cylindrical and enlarged into trunk with bilateral symmetry.

Scanning electron microscopic results: Under the scanning electron microscope, the parasite *Myxobolus* appeared pyriform and symmetrical shaped with anterior end tapering and posterior end bulb like with the size- of 8.72±0.45 µm x 5.96±0.36 µm.

The size was compared by morphometric analysis with the size of the parasite belonging to the group myxosporean. The shape of *Thelohanellus* was tear shaped, ellipsoidal and symmetrical with the outer smooth surface and the size of 10.16 µm x 3.90 µm while *Lernaea* showed anchors on the anterior side of the body, anterior ventral pair simple, dorsal pair T-shaped, two egg sacs on posterior side. Distance between two anchors of anchor worm observed under scanning electron microscope was 3.60 mm and the width of the stalk was 3.50 mm. Presence of four anchors on the anterior end showed characteristic similar to *Lernaea,* anchor worm.

DISCUSSION

Myxobolus Butschli, 1882 is one of the most diverse Cnidaria of class Myxozoa. These parasites are reportedly found in wide range of fishes including freshwater as well as marine

water. *Myxobolus cerebralis* (Hofer, 1903), causes whirling disease and some other species too have proved to be pathogenic to their hosts (Camus & Griffin 2010, Kaur& Attri, 2015). These parasites characterized as microscopic, multicellular and spore forming myxosporean. They develop histozoic or coelozoic plasmodia or pseudo cysts. Members of this genus are characterized by shell with smooth valves and two polar capsules. The parasites of same Genus collected during present study were compared with the myxosporean species having similar morphology. The identifying features of collected myxosporeans were; free living, ellipsoidal, symmetrical in shape with smooth spore valves and two polar capsules, converging anterior end giving slight oval appearance, round in shape posteriorly, containing prominent turns of polar filament, these filaments were arranged perpendicular to longitudinal axis of polar capsule and had average size of about 10 µm.

The data for comparison was obtained and found to have similarity with *M. pfeifferi* as infecting the gills and muscles of *Barbus barbus* (Thelohan, 1895). The characteristics up to genus level was similar to *M. orientalis* and *M. poljanskii* infecting the gills of *Carassius auratus gibelio* and *Pseudogobio rivularis* (Shulman 1962). And also similar to *M. ampullaceus* infection in fins of *Barbus kolus* and *M. chakravartyi*in the internal eye musculature of *Catla catla*. (Das & Sharma,1983; Lalitha Kumari, 1969). The present study was also found to have similarity with the findings reported by Kaur & Singh (2010) as they found similar infection of *Myxobolus punjabii* in *Labeo rohita* as the spore showed pyriform shape characterized with pointed anterior end and rounded posterior end. The present data also showed morphological similarity with other species as *Myxobolus dujardini* infection from intralamellae of gills of *Rutilus rutilus* and *M. catlae* infection from the gills of *L. rohita* (Chakravarty, 1943 & Thelohan, 1892). *Trichodina*, Ehrenberg, 1831 are the ciliophorans and known as ciliated ectoparasites of freshwater fishes (Lom & Dykova, 1992). They have been mostly studied in terms of their biology, distribution, pathogenicity and environmental impacts (Duran *et al*. 1991; Lom & Hoffman, 1964). This parasite affects the skin, gills and urogenital system of host fishes. It is a unicellular saucer-shaped ciliate parasite of size 40-60 µm in diameter and attack organs of fish by means of its cilia. Members of the genus are characterized mainly by the adhesive disc and the morphology of denticles on it and adoral ciliary spiral development. The individuals of this genus collected during present study were compared with ciliated protozoan parasite species having similar morphology. The ciliated form of parasite showed disc shaped body, with spiral ciliary adhesive discs and radial symmetry. The ring of interlocking cytoskeletal denticles was found to provides support and adhesion to surface including fish body tissue.
Similar *T. domerguei* infection have been reported in *F. jadranica* and *T. domerguei* in *F. gobii* morphometrically but it showed significant difference in terms of their denticle structures (Raabe, 1958). The parasites collected during present study showed morphometric resemblances with *T. jadranica* and *T. jadranicanoblei* infection (Lom, 1970). Morphological characteristics identified during present study was compared and found similar to that of *Trichodinella epizootica* infection and with *T. chandae sp.* infection from gills of *Chandanam* as parasite had saucer shaped body, with denticles on the adhesive disc and adoral ciliary spiral development (Raabe, 1950).

After *Myxobolus* Butschli, 1882 the sixth most prevalent genus is *Thelohanellus*, Kudo, 1933 (Zhao *et al.,* 2016). They form plasmodia with whitish cysts having microscopic spores' colony. Large cysts can be spotted easily with naked eye. And these parasites are characterized by single polar capsule and shell with smooth valves. The individuals of this genus collected during present study were compared with myxosporean species having similar morphology. They were characterized as free living, tear shaped, single polar capsule and shell with smooth valves, converging anteriorly, slightly oval in appearance and rounded in shape posteriorly, contains prominent turns in polar filament perpendicular to the longitudinal axis and had average size of about 10 µm.

Similar findings have been reported as *Thelohanellus dykovi* infection in *Labeo rohita* and *T. jiroveci* infection in the branchiae of *L. bata* (Kaur *et al.,* 2014; Kundu & Haldar, 1981). The spores of the isolated parasite were present within plasmodia and after rupturing plasmodia they showed anterior tapering end and posterior rounded end which were morphologically similar with the spores of *T. rohitae, T. jiroveci, T. valeti*, *T. zahrahae*, and *T. rodgii* in gill filaments of host fish (Molnar *et al*., 2006; Martins & Sauza, 1997; Martins *et al.*,1997). In the present study development of plasmodia within the gill filament and its degenerative process found similar to *T. dykovi* (Lom & Dykova, 1978). *Lernaea* Linnaeus, 1758, is an ectoparasite commonly called as anchor worm and has been reported in freshwater fishes (Hayward, 2006; Kabata, 1985). This copepod has been reported in host fishes from wild, aquarium, and culture and even in amphibians (Shariff *et al.,* 1986; Lester and Hayward, 2006). It has also been found in *Anguilla japonica* native to Japan (Harding, 1950). *Lernaea* infestation has been mostly reported in stagnant or slow-moving water and is most prevalent in summer season. It infects gills, fins, skins of the host fishes. Sexual dimorphism can be seen as female being larger than male, reproduction is by sexual mode and are carnivorous in nature as they feed on body fluids. They need >15° C temperature for reproduction and fishes are the intermediate and definitive hosts. Members of the genus are characterized by rounded knoblike head which holds the muscle of host fish body and 1-2 pairs of anchors to hold it.

Lernaea (anchor worm) as observed in present study, the genus is identified on the basis of having presence of anchors on the anterior side of the body, in case of females two egg sacs remain attached to it of the size 0.9-1cm. Cephalothorax having four horns varying slightly in length, anterior pair of ventral horn simple, dorsal pair is T-shaped, neck cylindrical and enlarges into trunk with bilateral symmetry. The present finding showed similarity with the finding of Hossain *et al*., (1978) as they described this parasite in teleost fish. Golder *et al*. (1987) and Rahman (1968) also reported *Lenaea cyprinacea* in fishes like tilapia, chital, singhi and khalisha from Bangladesh. Gnanamuthu *et al* (1951) have reported *Lernaea chackoensis* infection in fishes like *Osphronemus goramy* and *Catla catla* in Madras. Fryer *et al* (1956) have reported the same genus of parasite namely *L. bagri*, *L. tlapiae*, and *L. palate* from Nyasa Lake. Lewis *et al* (1981) have identified *L. craciata* in rock bass fishes in Ottawa river. Camburn *et al* (1983) have reported the same genus in fishes of family Cyprinaeidae. Ho *et al* (1997) have reported five species of the genus *Lernaea* from freshwater fishes in Thailand. Camburn *et al* (1983) have reported five species namely *Lernaea polymorpha*, *L. cyprinacea*, *L. oryzophyla, L.*

arcuata, *L. lophiara*. The present finding was compared with these data. The shape and prominent visible morphological features have provided the identification of species up to genus level.

CONCLUSION

The present study reports four genus of ectoparasites collected from gills surface and fins of freshwater fish *Labeo rohita* namely *Myxobolus, Trichodina, Thelohanellus* and *Lernaea.* These are reported by other authors as ectoparasites that cause debilitating effect on host. The present study reports ectoparasites identified on the basis of morphology up to genus level and also the case of multiple infestation of ectoparasites at the same time, which indicates towards the interspecific relations. The present study will help to understand about the ectoparasites: their external features, geographical location, change in morphology if any, their life cycle stages, their site of infestation, their host specificity, their organ specificity, their conducive environment, their effect on hosts, gross sign/ symptoms, cases of multiple infestation and prevalence etc. This will altogether help to achieve effective control measures through devising strategies. Some control strategies which can be adopted: by avoiding overcrowding, eliminating parasitic stage or intermediate host through occasional morphological identification of ectoparasites, surveillance and treatment. Extensive study on morphological as well as on molecular level should be carried out on protozoan and arthropodian ectoparasites related to fishes to understand their parasitic behavior as well as their pathogenicity and effect on the productivity of fish to avoid the economic losses.

REFERENCES

Ahmed, A. T. A. (1977). Morphology and life history of *Trichodina reticulata* from goldfish and other carps. *Fish Pathology, 12*(1), 21–31.

Asmat, G. S. (2002). Two new species of trichodinid ciliates (Ciliophora: Trichodinidae) from Indian fishes. *University Journal of Zoology, Rajshahi University, 21*, 31–34.

Basson, L., & Van As, J. G. (1987). Trichodinid (Ciliophora: Peritricha) gill parasites of freshwater fish in South Africa. *Systematic Parasitology, 9*, 143–151.

Basson, L., & Van As, J. G. (2006). Trichodinidae and other ciliophorans (phylum Ciliophora). In P. T. K. Woo (Ed.), *Fish diseases and disorders: Protozoan and metazoan infections* CAB International, *1*, 154–182.

Basu, S., & Haldar, D. P. (1999). *Thelohanellusbifurcata* n. sp., a new species of the genus *Thelohanellus* from hybrid carps and checklist of the species of the genus described from Indian fishes. *Proceedings of the Zoological Society (Calcutta), 52*, 115–124.

Basu, S., & Haldar, D. P. (2004). Description of three new species (Myxozoa: Myxosporea: Bivalvulida) of the genera *Myxobilatus* Davis, 1944 and *Myxobolus*Bütschli, 1882. *Acta Protozoologica, 43*(4), 337–343.

Basu, S., Modak, B. K., & Haldar, D. P. (2006). Synopsis of the Indian species of the genus *Thelohanellus* Kudo, 1933, along with description of *Thelohanellusdisporomorphus* sp. n. *Journal of Parasitology and Applied Animal Biology, 15*, 81–94.

Bauer, O. N. (1941). On the study of fish parasites of the Khatanga River. *Proceedings of the Scientific Research Institute of Polar Agriculture and Fishery, 16*, 121–125.

Bhuiyan, A. S., Akther, S., & Musa, G. M. (2007). Occurrence of parasites in *Labeo rohita* (Hamilton) from Rajshahi. *University Journal of Zoology, Rajshahi University, 26*, 31–34.

Calenius, G. (1980). *Parasites of fish in Finland III: Ciliates of the family Urceolariidae Dujardin, 1851*.

Camus, A. C., & Griffin, M. J. (2010). Molecular characterization and histopathology of *Myxobolus koi* infecting the gills of a koi, *Cyprinus carpio*, with an amended morphological description of the agent. *Journal of Parasitology, 96*(1), 116–124. https://doi.org/10.1645/GE-2113.1

Dar, S. A., Kaur, H., & Chishti, M. Z. (2016). Morphological and histopathological description of *Myxobolusnigerae* n. sp. infecting gills of a cold-water native cyprinid fish, *Schizothoraxniger*, from Wullar Lake, India. *Species, 17*, 109–118.

Daszak, P., Cunningham, A. A., & Hyatt, A. D. (2000). Emerging infectious diseases of wildlife-Threats to biodiversity and human health. *Science, 287*(5452), 443–449.

Dogiel, V. (1956). *Parasitology of fishes*. Leningrad University Press.

Donec, Z. S. (1984). Key to parasites of freshwater fish of the USSR. In S. S. Shulman (Ed.), *Parasitic protozoa* (O. N. Bauer, Ed.). Nauka.

Ergens, R., & Lom, J. (1970). *Causative agents of fish diseases*. Academia.

Feist, S. W., & Longshaw, M. (2006). Phylum Myxozoa. In P. T. K. Woo (Ed.), *Fish diseases and disorders: Vol. 1. Protozoan and metazoan infections* (pp. 230–296). CAB International.

Gupta, A., & Kaur, H. (2017). A new pathogen, *Myxobolusholzerae* (Myxosporea: Myxozoa), causing severe gill disease in an Indian major carp, *Labeo rohita*, in a cold-water wetland, Punjab, India. *Microbial Pathogenesis, 111*, 244–251.

Gupta, A., & Kaur, H. (2017). A new pathogen, Myxobolusholzerae (Myxosporea: Myxozoa) causing severe gill disease in an Indian major carp Labeo rohita in a cold-water wetland, Punjab (India). Microbial pathogenesis, 111, 244-251.

Hagargi, S. S. (1979). Observations on *Thelohanellusrodgii* n. sp. (Protozoa: Myxosporidia) from a freshwater teleost. In *Proceedings of the National Congress of Parasitology* (p. 56). Varanasi.

Hagargi, SS. Observations on Thelohanellusrodgii n. sp. (Protozoa: Myxosporidia) from a freshwater teleost. Proc.Natl. Cong. Parasitol, Varanasi. 1979, p. 56

Haldar, D. P., Das, M. K., & Sharma, B. K. (1983). Studies on protozoan parasites from fishes: Four new species of the genera *Henneguya* Thélohan, 1892, *Thelohanellus* Kudo, 1933, and *Myxobolus*Bütschli, 1892. *Archiv für Protistenkunde, 127*(3), 283–296.

Haldar, D. P., Samal, K. K., & Mukhopadhyay, D. (1997). Studies in the protozoan parasites of fishes in Orissa: Five new species of the genera *Henneguya*, *Thelohanellus*, and *Unicauda* (Myxozoa: Bivalvulida). *Journal of the Bengal Natural History Society, 16*, 50–63.

Harding, J. P. (1950). On some species of *Lernaea*. *Bulletin of the British Museum (Natural History), Zoology, 1*, 3–27.

Heckman, R. (1996). Protozoan parasites of fish, part 1. *Aquatic Magazine, 22*(3), 44–57.

Hemananda, T., Mohilal, N., Bandyopadhyay, P. K., & Mitra, A. K. (2010). *Thelohanellusimphalensis* sp. nov.

(Myxozoa) infecting gills of a major carp *Labeorohita* Hamilton, 1822, from Thoubal, Manipur, India. *Protistology, 6*, 280–283.

Hoffman, G. L. (1967). *Parasites of North American freshwater fishes*. University of California Press.

Hoffman, G. L. (1998). *Parasites of North American freshwater fishes* (2nd ed.). University of California Press.

Hossain, M. M. M., Rahman, M. Z., Islam, M. A., Alam, M. E., & Rahman, H. (2013). *Lernaea* (anchor worm) investigations in fish. *International Journal of Agricultural and Food Security, 1*, 12–19.

Iwanowicz, D. D. (2011). Overview on the effects of parasites on fish health. In *Proceedings of the Third Bilateral Conference between Russia and the United States: Bridging America and Russia with shared perspectives on aquatic animal health* (pp. 176–184).

Jayasankar, P. (2018). Present status of freshwater aquaculture in India: A review. *Indian Journal of Fisheries, 65*(4), 157–165. https://doi.org/10.21077/ijf.2018.65.4.81300-20

Kabata, Z. (1985). *Parasites and diseases of fish cultured in the tropics*. Taylor & Francis.

Kaur, H. and Singh, R. (2010a). A new myxosporean species Myxobolussclerii sp. nov. and one known species M. stomum Ali *et al*. (2003) from two Indian major carp fishes. Journal of Parasitic Diseases. 34:33-39.

Kaur, H. and Singh, R. (2011a). Two new species of Myxobolus (Myxozoa: Myxosporea: Bivalvulida) from freshwater fishes of Punjab wetlands (India). Journal of Parasit Diseases. 35:33-41.

Kaur, H. and Singh, R. (2011c). Two new species of Myxobolus (Myxozoa: Myxosporea: Bivalvulida) infecting an Indian major carp and a cat fish in wetlands of Punjab, India. Journal of Parasitic Diseases. 35:169-176.

Kaur, H. and Singh, R. (2011d). Two new species of Myxobolus (Myxozoa: Myxosporea: Bivalvulida) infecting Indian freshwater fishes in Punjab wetlands (India). Parasitology Research. 108:1075-1082.

Kaur, H., &Attri, R. (2015). Prevalence and tissue specificity of *Myxobolussaugati* Kaur and Singh, 2011 (Myxozoa: Myxosporea: Bivalvulida) causing dermal myxoboliosis in wild and cultured Indian major carps in Punjab. *Species, 15*(47), 14–18.

Kaur, H., & Singh, R. (2010). A new myxosporean species, *Myxobolussclerii* sp. nov., and one known species, *M. stomum* Ali *et al*. (2003), from two Indian major carp fishes. *Journal of Parasitic Diseases, 34*, 33–39. https://doi.org/10.1007/s12639-010-0010-7

Kaur, H., & Singh, R. (2011a). Two new species of *Myxobolus* (Myxozoa: Myxosporea: Bivalvulida) from freshwater fishes of Punjab wetlands, India. *Journal of Parasitic Diseases, 35*, 33–41. https://doi.org/10.1007/s12639-011-0024-9

Kaur, H., & Singh, R. (2011b). Two new species of *Myxobolus* (Myxozoa: Myxosporea: Bivalvulida) infecting an Indian major carp and a catfish in wetlands of Punjab, India. *Journal of Parasitic Diseases, 35*, 169–176. https://doi.org/10.1007/s12639-011-0061-4

Kaur, H., & Singh, R. (2011c). Two new species of *Myxobolus* (Myxozoa: Myxosporea: Bivalvulida) infecting Indian freshwater fishes in Punjab wetlands, India. *Parasitology Research, 108*, 1075–1082.

Kaur, H., Dar, S. A., & Katoch, A. (2014). *Thelohanellusdykovi* sp. nov. (Myxozoa: Bivalvulidae), a pathogenic gill parasite in cultured Indian major carp, *Labeorohita* (Hamilton, 1822), in Punjab, India. *Species, 10*(23), 24–30.

Kent, M. L., Andree, K. B., Bartholomew, J. L., El-Matbouli, M., Desser, S. S., Devlin, R. H., Feist, S. W., Hedrick, R. P., Hoffmann, R. W., Khattra, J., Hallett, S. L., Lester, R. J. G., Longshaw, M., Palenzuela, O., Siddall, M. E., & Xiao, C. (2001). Recent advances in our knowledge of the Myxozoa. *Journal of Eukaryotic Microbiology, 48*(4), 395–413. https://doi.org/10.1111/j.1550-7408.2001.tb00173.x

Klinger, R., & Floyd, R. F. (2002). *Introduction to freshwater fish parasites* (Document CIR716). Institute of Food and Agricultural Sciences, University of Florida.

Kumari, P. L. (1969). Studies on parasitic protozoa (Myxosporidia) of freshwater fishes of Andhra Pradesh, India. *Rivista di Parassitologia, 30*, 153–226.

Kundu, T.K., Haldar, D.P. (1981). Studies in Thelohanellusjirovecisp.nov. a new myxosporidian parasite in a common teleost fish. *Vest. Cesk. Spol. Zool,* 45, 94-101

Lalitha Kumari, P. 1969. Studies on parasitic Protozoa (Myxosporidla) of freshwater fishes of Andhra Pradesh, India. Riv. Parassitol. 30:153-226.

Lester, R. G., & Hayward, C. J. (2006). Phylum Arthropoda. In P. T. K. Woo (Ed.), *Fish diseases and disorders: Vol. 1. Protozoan and metazoan infections* (pp. 466–565). CAB International.

Lilley, J. H., Phillips, M. J., &Tonguthai, K. (1992). *A review of epizootic ulcerative syndrome (EUS) in Asia*. Aquatic Animal Health Research Institute and Network of Aquaculture Centres in Asia-Pacific.

Lom, J. (1970). Protozoa causing diseases in marine fishes. In S. F. Snieszko (Ed.), *A symposium on diseases of fishes and shellfishes* (Vol. 5, p. 101). American Fisheries Society.

Lom, J. (1973). The adhesive disc of *Trichodinellaepizootica*: Ultrastructure and injury to the host tissue. *Folia Parasitologica, 20*(3), 193–202.

Lom, J., &Dyková, I. (1978). Histopathological changes in fish gills infected with myxosporidian parasites of the genus *Henneguya*. *Journal of Fish Biology, 12*, 197–202.

Lom, J., &Dyková, I. (1992). *Protozoan parasites of fishes*. Elsevier.

Lom, J., & Hoffman, G. L. (1964). Geographic distribution of some species of trichodinids (Ciliata: Peritricha) parasitic on fishes. *The Journal of Parasitology*, 30–35.

Markov, G. S., Dogiel, V. A., Petrushevesky, G. K., &Polyansky, Y. U. I. (1961). *Parasitology of fishes*.

Martins, M. L., Souza, V. N., Moraes, F. R., Moraes, J. R. F., Costa, A. J., & Rocha, U. F. (1997). Pathology and behavioral effects associated with *Henneguya* sp. (Myxozoa: Myxobolidae) infections of captive pacu, *Piaractusmesopotamicus*, in Brazil. *Journal of the World Aquaculture Society, 28*, 297–300.

Molnár, K., Székely, C., Mohamed, K., &Shaharom-Harrison, F. (2006). Myxozoan pathogens in cultured Malaysian fishes. I. Myxozoan infection of the sutchi catfish. *Diseases of Aquatic Organisms, 68*, 209–218.

Mukhopadhyay, D., & Haldar, D. P. (2004). *Thelohanellusendodermitus* sp. n.: A new myxozoan (Myxozoa: Bivalvulida) from the major carp, *Labeorohita* (Hamilton-Buchanan), in a sewage farm in West Bengal, India. *Environment and Ecology, 22*, 139–142.

Qadri, S. S. (1962). New myxosporidian from the Indian freshwater fish, *Labeofimbriatus* II: *Thelohanellusandhrae* sp. n. *Zeitschrift für Parasitenkunde, 21*, 517–520.

Sanmartín Durán, M. L., Fernández Casal, J., Tojo, J. L., Santamarina, M. T., Estévez, J., &Ubeira, F. (1991). *Trichodina* sp.: Effects on the growth of farmed turbot (*Scophthalmus maximus*). *Bulletin of the European Association of Fish Pathologists, 11*, 89–91.

Sarkar, N. K. (1993). On two new species of *Myxobolus* Bütschli, 1882 (Myxozoa: Myxosporea) from some freshwater fish of West Bengal, India. *Proceedings of the Zoological Society (Calcutta), 46*(1), 61–66.

Sarkar, N.K. (1993). On two new species of Myxobolus Butschli, 1882 (Myxozoa: Myxosporea) from some freshwater fish of West Bengal, India. Proceedings of Zoological Society, Calcutta. 46(1):61-66.

Shariff, M., Kabata, Z., & Sommerville, C. (1986). Host susceptibility to *Lernaeacyprinacea* L. and its treatment in a large aquarium system. *Journal of Fish Diseases, 12*, 393–401.

Smith, K. F., Sax, D. F., & Lafferty, K. D. (2006). Evidence for the role of infectious disease in species extinction and endangerment. *Conservation Biology, 20*(5), 1349–1357. https://doi.org/10.1111/j.1523-1739.2006.00524.x

Southwell, T., & Prashad, B. (1918). Notes from the Bengal Fisheries Laboratory, No. 5: Parasites of Indian fishes, with a note on the carcinoma in the climbing perch. *Records of the Indian Museum (Calcutta), 15*, 341–355.

Tripathi, Y. R. (1959). Monogenetic trematodes from fishes of India. *Indian Journal of Helminthology, 9*(1–2), 1–149.

Yamaguti, S. (1963). *Parasitic Copepoda and Branchiura of fishes*. Interscience Publishers.

Zhao, D., Borkhanuddin, M. H., Wang, W., Liu, Y., Cech, G., Zhai, Y., & Székely, C. (2016). The life cycle of *Thelohanelluskitauei* (Myxozoa: Myxosporea) infecting common carp (*Cyprinus carpio*) involves aurantiactinomyxon in *Branchiurasowerbyi*. *Parasitology Research, 115*(11), 4317–4325. https://doi.org/10.1007/s00436-016-5215-y

****